

Expression of Nitric Oxide Synthase in Primary and Recurrent Pterygium

Primer ve Tekrarlayan Pteryjumlarda Nitrik Oksid Sentaz Ekspresyonu

Sinan Emre, Seda H. Vatansever*, Elgin Türköz*, Özcan R. Kayıkçıoğlu

Celal Bayar University, School of Medicine, Department of Ophthalmology, Manisa, Turkey

*Celal Bayar University, School of Medicine, Department of Histology and Embryology, Manisa, Turkey

Summary

Purpose: The aim of this study was to investigate the expression of different nitric oxide synthases (NOSs) in primary and recurrent pterygia and to investigate the probable role of any nitric oxide synthase on pterygium recurrence.

Materials and Method: Specimens of 40 primary pterygia and 10 recurrent pterygia excised during pterygium surgery were included in the study. Also, 15 normal conjunctiva of medial limbus obtained from patients free of pterygia and removed during other ophthalmologic surgeries formed the control group. Specimens were stained with hematoxylin and eosin for general histological and morphologic evaluation. The distribution of n-NOS, e-NOS and i-NOS were analyzed using indirect immunoperoxidase staining.

Results: Histological evaluation of specimens revealed that the epithelium in primary and recurrent pterygia groups was thicker compared to that in the control group. Immunohistochemical analysis revealed that in both primary pterygium and control groups, immunoreactivity was positive for all NOSs in both epithelium and connective tissue. For recurrent pterygium group, NOS immunoreactivity could be detected moderately for n-NOS in the epithelium and weakly for e-NOS in both epithelium and connective tissue. However, in recurrent pterygium samples, i-NOS immunoreactivity was lacking in both epithelium and connective tissue.

Discussion: These data are the first to demonstrate that NOS expression may differ between primary and recurrent pterygia. Meanwhile, continuous expression of n-NOS with suppression of i-NOS and e-NOS may be an important step in the recurrence process of pterygia. (*Turk J Ophthalmol* 2012; 42: 166-71)

Key Words: Nitric oxide, nitric oxide synthase, pterygium, recurrent pterygium

Özet

Amaç: Bu çalışmanın amacı primer ve tekrarlayan pteryjium dokularında nitrik oksid sentetaz enzimlerinin ekspresyonunu araştırmak ve pteryjium tekrarı üzerine nitrik oksid sentetazın muhtemel rolünü araştırmaktır.

Gereç ve Yöntem: Pteryjium cerrahisi sonrası elde edilen 40 primer pteryjium ve 10 tekrarlayan pteryjium dokusu çalışmaya dahil edildi. Ayrıca başka oftalmolojik cerrahiler için operasyona alınan 15 hastanın medial limbusundan alınan konjonktiva örnekleri ile kontrol grubu oluşturuldu. Örnekler histolojik ve morfolojik değerlendirme amacıyla hematoksilin ve eozin boyası ile boyandı. Örneklerdeki n-NOS, e-NOS ve i-NOS dağılımları immunperoksidaz yöntemi ile değerlendirildi.

Sonuçlar: Örneklerin histolojik değerlendirmesi, primer ve tekrarlayan pteryjium gruplarının epitellerinin kontrol grubuna göre daha kalın olduğunu ortaya koymuştur. İmmunohistokimyasal analiz, primer pteryjium ve kontrol gruplarının, epitelyum ve bağ dokusu tabakasının herikisinde de tüm NOS türleri için immunoreaktivitenin pozitif olduğunu ortaya koymuştur. Tekrarlayan pteryjium grubunda ise, epitelde n-NOS için orta şiddette immunreaktivite izlenirken, e-NOS hem epitelde hemde bağ dokusunda zayıf pozitiflik göstermektedir ancak i-NOS immunreaktivitesi gerek epitelyum tabakasında gerek ise bağ dokusu tabakasında maalesef izlenmemektedir.

Tartışma: Bu bulgular primer ve tekrarlayan pteryjiumlarda NOS ekspresyonunun farklı olabileceğini göstermektedir. Ayrıca, cerrahiden sonraki pteryjiumun tekrarlama sürecinde n-NOS ekspresyonu sürer iken, i-NOS ve e-NOS ekspresyonunun baskılanmasının tekrarlama sürecinde önemli basamaklar olabileceğini düşündürmektedir. (*Turk J Ophthalmol* 2012; 42: 166-71)

Anahtar Kelimeler: Nitrik oksid, nitrik oksid sentaz, pteryjium, tekrarlayan pteryjium

Address for Correspondence/Yazışma Adresi: Dr. Sinan Emre, Celal Bayar University, School of Medicine, Department of Ophthalmology, Manisa, Turkey

Tel.: +90 236 444 42 28 Gsm: +90 532 302 11 38 E-posta: mdsinanemre@yahoo.com **Received/Geliş Tarihi:** 29.11.2011 **Accepted/Kabul Tarihi:** 06.02.2012

Introduction

Pterygium is growth of fibrovascular tissue onto the cornea that is continuous with the conjunctiva. It occurs in the interpalpebral fissure, usually bilateral and more common at the nasal side.¹ It is commonly wing shaped. The centripetally invading pterygium epithelium is associated with stromal overgrowth of fibroblasts and blood vessels which are accompanied by an inflammatory cell infiltrate and an abnormal extracellular matrix accumulation.² Pterygium causes squamous metaplasia, goblet cell hyperplasia and breakdown of Bowman's layer in the cornea and is characterized by a hypertrophic-elastotic degenerative connective tissue.^{3,4}

In the etiopathogenesis of pterygium, the role of chronic exposure to ultraviolet light has been shown in several studies.⁵⁻⁷ The typical location of pterygium is explained by corneal focusing of light on the medial limbus, and the alteration of limbal stem cells secondary to chronic UV light exposure has been accepted as the initial biologic event in pterygium pathogenesis.^{8,9} In addition to UV light, studies in recent years revealed the role of genetic susceptibility,¹⁰ anti-apoptotic mechanisms,¹¹ cytokines,¹² growth factors,¹³ matrix metalloproteinases,³ immunologic mechanisms,¹⁴ and viral infections¹⁵ in the pathogenesis of this disease. However, the development mechanism of pterygium could not be explained completely yet. Recently, a study showed the protective capacity of nitric oxide (NO) against the damage induced by UVA.¹⁶

NO is a highly reactive and short-lived molecule produced by the enzyme nitric oxide synthase (NOS) and L-arginine serves as the sole substrate. This reaction is catalyzed by one of the three isoforms of NOS; neuronal NOS (nNOS), endothelial NOS (eNOS) and inducible NOS (iNOS). Each isoform exhibits unique expression patterns and unique mechanisms of regulation. Two of the enzymes (eNOS and nNOS) are always present, however, the iNOS is expressed in cells only after stimulation of the cells with cytokines, microbes, microbial products. While the NO produced by eNOS and nNOS takes role in fundamental physiologic processes like vascular hemostasis and neurotransmission, the NO produced by iNOS has role in regulation of intercellular matrix, and proinflammatory processes like cell death and tissue injury.¹⁷ Previously, the potential role of NO and iNOS in the etiopathogenesis of primary pterygium has been studied, but to our knowledge, the probable role of eNOS and nNOS has not been studied in primary pterygium.^{18,19} Also, up to now, none of NOSs have been studied in recurrent pterygium.

The purpose of this study was to describe the distribution of NOS among primary and recurrent pterygium tissues and to compare these results with healthy conjunctival tissue as controls.

Methods

In compliance with the provisions of the Declaration of Helsinki, relevant patient, demography, diagnosis, clinical data and surgical procedure were retrospectively retrieved for patients who had undergone excision of the head, body and fibrovascular tissue of 40 primary pterygia and 10 recurrent pterygia. Normal corneal-conjunctival junction samples from the nasal conjunctiva (2x2 mm) obtained from 15 patients, who had undergone other ophthalmologic surgeries, served as a control group. None of the patients included in the study had any ocular or systemic inflammatory or immunosuppressive condition. To be included in the study, informed consent was obtained from both pterygium and control groups.

The study included patients who have been operated for primary or recurrent pterygium in the Department of Ophthalmology at Celal Bayar University. The eyes which have been previously operated at our clinic and presented with new pterygia at the same location were accepted as recurrent pterygium. The control group consisted of patients who had undergone other ophthalmologic surgeries like age-related cataract surgery or retinal detachment surgery.

Tissue sections were obtained from the head of the pterygium and the samples were fixed in 10% formaldehyde for 24-48 hours; the samples were then put in 100% ethanol for 20 hours. They were then incubated for 5 hours in chloroform and then for 5 hours in paraffin. The 5 μ sections from paraffin blocks were stained with hematoxylin and eosin (H&E) for general histological and morphologic evaluation. The distribution of n-NOS, e-NOS and i-NOS was analyzed using indirect immunoperoxidase staining.

For histochemical evaluation, sections were dewaxed at 60 °C overnight, immersed in xylene for one hour and then rehydrated through a graded series of ethanol (100%, 95%, 80%, 70%, and 60%) for 2 minutes for each concentration, followed by a wash in tap water. Sections were stained with either hematoxylin (01562E, Surgipath, Bretton, Peter Borough, Cambridgeshire) or eosin (01602E, Surgipath, Bretton, Peter Borough, Cambridgeshire) according to their routine protocols. Slides were mounted using mounting media and covered with glass cover slips prior to viewing, and examined and photographed with Olympus BX-40 (Tokyo, Japan) light microscope.

For immunohistochemical evaluation, the sections were incubated at 60 °C overnight and then dewaxed in xylene for 30 min. After soaking in a decreasing series of ethanol, the sections were washed with distilled water. They were then treated with 2% trypsin in 50 mM Tris buffer (pH 7.5) at 37 °C for 15 min, and washed with phosphate-buffered saline (PBS). The sections were delineated with an Elite Pap pen (DBS, Pleasanton, CA, USA) and incubated in 3% H₂O₂

solution for 15 min to inhibit endogenous peroxidase activity. They were washed 3 times for 5 min with PBS and incubated with primary antibodies, to endothelial NOS (anti-eNOS RB-1711, Neomarkers, Fremont, CA, dilution 1:200), inducible nitric oxide synthase (anti-iNOS RB-1605, Neomarkers, Fremont, CA, dilution 1:100) and neuronal nitric oxide synthase (anti-nNOS, 617000, Zymed, San Francisco, USA, dilution 1:100) for 18 h. The sections were then incubated with biotinylated IgG (supplied ready to use) for 30 min, followed by three washes in PBS and then with streptavidin-peroxidase conjugate (supplied ready to use) for 30 min (KP-500, Universal Phosphatase Kit, Diagnostic BioSystems, Pleasanton, CA, USA) and washed with PBS three times. They were then incubated with a solution containing AEC (3-amino-9-ethylcarbazole, TA-002-HAC, Lab Vision, Fremont, CA) 50 μ l for each section for 5 min to visualize immunolabeling, and after rinsing with distilled water counterstained with Mayer's hematoxylin (72804E, Microm, Walldorf, Germany). The sections were dehydrated with 80% and 95% alcohol and immersed in xylene and covered with mounting media (01730 Surgipath, Bretton, Peter Borough, Cambridgeshire). The negative controls received the same treatment as described above, but were incubated with rabbit IgG or mouse IgG instead of the primary antibodies.

Data Analysis

The staining intensity was graded semi-quantitatively and the HSCORE was calculated using the following equation: $HSCORE = \sum Pi (i+1)$, where i = intensity of staining with a value of 1, 2 or 3, (weak, moderate, or strong, respectively) and Pi is the percentage of stained cells for each intensity, varying from 0% to 100%.

The software SPSS 10.0 for Windows (SPSS, Chicago, IL, USA) was used for statistical evaluation. All values in the text are expressed as mean \pm SEM. Differences among groups were statistically analyzed with one-way analysis of variance (ANOVA), where appropriate. The results were analyzed by one-way ANOVA. A p -value of <0.05 was considered as statistically significant.

Results

Demographic features of patients are shown in Table 1. Histological evaluation of specimens revealed that the epithelium of control group included few Goblet cells and was characterized

Table 1. Demographic features of patients according groups

	Primary Pterygia	Recurrent Pterygia	Control group
Gender (M / F)	19 / 21	6 / 4	9 / 6
Mean age \pm SD(years)	48.3 \pm 10.1	49.8 \pm 11.3	47.8 \pm 7.5

by multilayered squamous cells (Figure 1A). However, in primary (Figure 1B) and recurrent (Figure 1C) pterygium sections, epithelium was thicker compared to the control group and hypertrophic Goblet cells, which are more pronounced in primary pterygium tissues, were detected (Figure 1).

In immunohistochemical investigation, iNOS immunoreactivity in the control group was positive in both epithelial and connective tissue (191.6 ± 19.0 , 76.4 ± 7.6 , respectively), but staining was more prominent in the epithelium level (Figure 2A, Table 2). Meanwhile, in the control group, while eNOS and nNOS immunoreactivities were detected in both epithelial and connective tissues, these

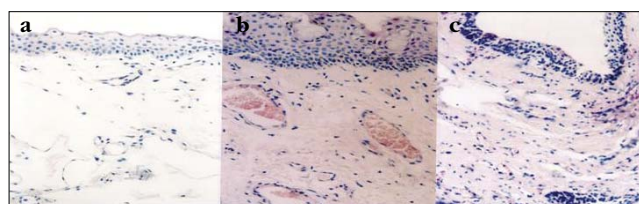


Figure 1. Histological evaluation of control (A), primary pterygium (B), recurrent pterygium (C) samples. H&E X 200

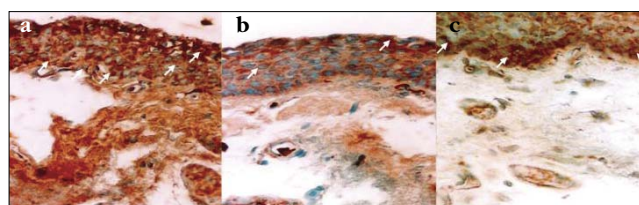


Figure 2. Distribution of iNOS (A), eNOS (B), and nNOS (C) in the control group. Higher immunoreactivity has been detected for iNOS compared to eNOS and nNOS. Immunoreactivity was detected cytoplasmically and labelled with white arrows. X400

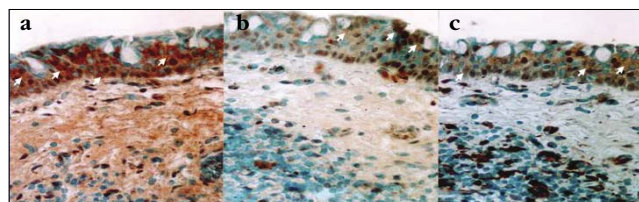


Figure 3. Distribution of iNOS (A), eNOS (B), and nNOS (C) in the primary pterygium group. Higher immunoreactivity has been detected for iNOS compared to eNOS and nNOS. Immunoreactivity was detected cytoplasmically and labelled with white arrows. X400

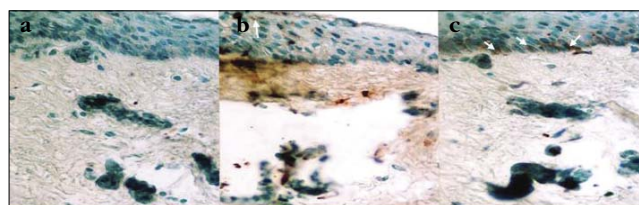


Figure 4. Distribution of iNOS (A), eNOS (B), and nNOS (C) in the recurrent pterygium group. Despite the negativity of iNOS and eNOS, positive immunoreactivity has been detected for nNOS. Immunoreactivity was detected cytoplasmically and labelled with white arrows. X400

immunoreactivities were more clear in the epithelial tissue (Figure 2B and 2C, Table 2). Among primary pterygia, the immunoreactivity of all NOSs was positive in the epithelium, particularly in the basal cells (Figure 3 A-C), and the intensities detected were 195.6 ± 12.0 for iNOS, 33 ± 6.03 for eNOS and 84 ± 7.51 for nNOS. The iNOS, eNOS and nNOS immunoreactivities were also detected in the connective tissue of primary pterygium, but eNOS immunoreactivity was less than the other NOS intensities (Table 2). On the other hand, among recurrent pterygia, while iNOS immunoreactivity was negative, weak eNOS immunoreactivity was detected in both epithelium and connective tissues (8.8 ± 0.8 , 8.8 ± 0.8 , respectively) (Figure 4 A, B). In addition, nNOS immunoreactivity was only detected moderately in the epithelium (Figure 4 C). Distribution of different NOSs in both epithelium and connective tissue of samples among the study groups are shown in Table 2.

Discussion

There is compelling evidence that UV-mediated limbal damage acts as a trigger for pterygium pathogenesis.⁵⁻⁷ Recent studies have suggested that p53 and human papillomavirus may also be implicated in the pterygium pathogenesis.^{20,21} UV radiation can cause mutations in genes such as the p53 tumor suppressor gene, resulting in its abnormal expression in the pterygial epithelium.²² These findings suggested that pterygium is not just a degenerative lesion, but could be a result of uncontrolled cell proliferation.

Bredt and Snyder first isolated NO synthesizing enzyme from the rat cerebellum.²³ The neuronal NOS (nNOS) is constitutively expressed in the brain, peripheral nerves, and kidneys. Inducible NOS (iNOS) is not constitutively expressed but is induced in macrophages with bacterial lipopolysaccharide and cytokines.

Endothelial NOS (eNOS) is constitutively expressed mostly in endothelial cells.²⁴

NO is an inorganic, labile gaseous molecule that is released from endothelial cells. The endothelial NO has antiplatelet, antithrombotic, antiproliferative, and antiatherosclerotic actions. Therefore, endothelial dysfunction results in circulatory disorders in the eye.²⁴ Since NO is a free radical, it is a highly reactive molecule within biological systems. One of these interactions of NO includes DNA damage. One of the consequences of the NO-mediated DNA damage is to trigger p53 accumulation, which can induce apoptosis. Interestingly, it has been demonstrated that a negative feedback loop is formed between NO-generation and p53 and, accumulation of p53 results ultimately in down-regulation of iNOS expression by inhibition of iNOS promoter activity.²⁵

It has been documented that in tumors, NO generated by NOS (located either within the tumor or in the surrounding stroma) may promote new blood vessel formation by up-regulating VEGF. This neovascularization enhances the ability of the tumor to grow and increases its invasiveness and metastatic ability.²⁵

Xu et al.²⁵ described the NO as a “Doubled-Edged Sword” in cancer. Although the high concentrations of NO might mediate cancer cell apoptosis and the inhibition of cancer growth, the relatively low concentrations of NO promote the tumor growth. Increased NO-generation in a cell may select mutant p53 cells and might contribute to tumor angiogenesis by up-regulating VEGF.²⁵ Similar to pterygium, cutaneous melanoma is a disease in which precise etiology has not been defined clearly. Recently, the importance of nNOS genetic variability as a biomarker for susceptibility to cutaneous melanoma has been shown.²⁶

Up to now, NO and NOS have been studied in so many different systemic and ocular diseases. The role of different NOS in various ophthalmologic diseases such as glaucoma,

Table 2. Staining intensities of iNOS, eNOS and nNOS among study groups at epithelium and connective tissues

	iNOS		eNOS		nNOS	
	Connective Tissue	Epithelium	Connective Tissue	Epithelium	Connective Tissue	Epithelium
Primary Pterygium	++ $45 \pm 3.7 \dagger$	+++ $195.6 \pm 12.0 \text{ ¥}$	+ 8.4 ± 0.7	+/ $33 \pm 6.0 *$	++ 34.8 ± 1.9	++ $84 \pm 7.5 \dagger$
Recurrent Pterygium	- $0 \ddagger$	- $0 \ddagger$	+ 14 ± 1.4	+ $8.8 \pm 0.8 \ddagger$	- 0	++ $34.8 \pm 2.7 *$
Control group	+++ 76.4 ± 7.6	+++ 191.6 ± 19.0	++ 13.6 ± 2.1	+++/ 76.8 ± 14.8	+ 6 ± 0.6	+++/ 87 ± 18.9

* p <0.05 Statistically significant compared to control group,

† p <0.05 Statistically significant compared to recurrent pterygium group,

‡ p <0.001 Statistically significant compared to control group,

¥ p <0.001 Statistically significant compared to recurrent pterygium group

cataract, and diabetic retinopathy has been extensively investigated.²⁴ However, the role of NOS has been first studied in the pterygium pathophysiology by Lee et al.¹⁹ In that study, the authors documented the increase of VEGF and iNOS immunoreactivity in pterygium epithelium and the imperative role of these molecules have been discussed. Immunoreactivity of iNOS and VEGF was mainly detected in the pterygial epithelium and the authors pointed the close relation of these molecules. Similar to our results, they showed intense immunohistochemical staining for iNOS in primary pterygia. In contrast to our results, they could not detect immunohistochemical staining for iNOS in the epithelial portion of control samples. Since the authors did not study the recurrent pterygia in their research, we could not make any comparison between the two studies in that respect.

Following that study, the role of NO and superoxide dismutase (SOD) in pterygium has been investigated by Ozdemir et al. and the authors documented significantly lower levels for both molecules compared to controls.¹⁸ The authors described these relatively lower levels as a result of either decreased production or increased consumption. Our findings support this study and we found that the relatively lower levels of NO could be the result of decreased production by NOSs.

As shown previously, basal release of NO acts as an antioxidant against harmful free radicals such as superoxide anions and hydrogen peroxide.²⁷ According to Benz et al., inadequate NO release leads to undetection of other free radicals and, therefore, initiate tissue damage.²⁸ So that, the results of previous studies and our findings showed that relatively lower level of NO, particularly NO produced by eNOS and iNOS, may be the key factors in the recurrence of pterygium.

Except NOSs, the production of NO could also be provided through vascular metabolic activation of organic nitrites that could be triggered by UVA.²⁹ The presence of this pathway in the conjunctiva has been previously documented by Peponis et al.³⁰ The probable role of these pathways in the pterygium pathophysiology is a subject of further investigation.

In our study NOS expression has been detected in both primary and recurrent pterygia. In primary pterygium, the positivity of all three NOSs has been detected in both epithelium and connective tissue (Table 2). In our study, iNOS expression in primary pterygium tissue was more significant compared to eNOS and nNOS. In concordant with previous reports,¹⁹ our study confirmed the positive relation between iNOS and primary pterygium. Most likely, during the development of primary pterygium, iNOS acts in favor of this process.

On the other hand, in recurrent pterygium, nNOS immunoreactivity was positive in the epithelium, despite the negative immunoreactivity of iNOS and weak

immunoreactivity of eNOS in both epithelium and connective tissue. Absence of iNOS and weak expression of eNOS may be the major impact factors in the recurrence of pterygia. When we overlook the functions of eNOS and iNOS, eNOS is constitutively expressed and primarily takes role in maintaining the vascular hemodynamics of tissues. On the other hand, expression of iNOS is induced under certain circumstances. Taken all together, it seems that cessation of iNOS and eNOS expression by any internal or external factors may be a potent stimulus or an indicator of pterygium recurrence through triggering various growth factors including vascular endothelial growth factor. For recurrent pterygia, probably nNOS gets the main role instead of iNOS. As a hypothesis, persistent exposure to certain triggering factors as sunlight could induce the sustained expression of nNOS while depressing the expression of iNOS and eNOS.

As a conclusion, the expression of NOS varies in primary and recurrent pterygia. Meanwhile, the decrease of iNOS and eNOS expression and continuous expression of nNOS may be a biomarker for prediction of pterygium recurrence. For these reasons, documentation of NOS expression among primary and recurrent pterygia may be a useful parameter for understanding the pterygium development mechanism and for follow-up of the patients. We believe that further studies are necessary to elucidate the role of different NOSs and NO in the etiopathology of pterygium development and recurrence.

References

1. Farjo Q, Sugar A. Conjunctival and corneal degenerations. In Yanoff M, Duker JS, editors. *Ophthalmology*. St. Louis: Mosby, 2004:446-53.
2. Di Girolamo N, Chui J, Coroneo MT, Wakefield D. Pathogenesis of pterygia: role of cytokines, growth factors, and matrix metalloproteinases. *Prog Retin Eye Res*. 2004;23:195-228.
3. Naib-Majani W, Eltohami I, Wernet N, et al. Distribution of extracellular matrix proteins in pterygia: an immunohistochemical study. *Graefes Arch Clin Exp Ophthalmol*. 2004;42:332-8.
4. Touhami A, Di Pascuale MA, Kawatika T, et al. Characterisation of myofibroblasts in fibrovascular tissues of primary and recurrent pterygia. *Br J Ophthalmol*. 2005;89:269-74.
5. Moran DJ, Hollows FC. Pterygium and ultraviolet radiation: a positive correlation. *Br J Ophthalmol*. 1984;68:343-6.
6. Sekelj S, Dekaris I, Kondza-Krstonjivić E, et al. Ultraviolet light and pterygium. *Coll Antropol*. 2007;31:45-7.
7. Threlfall TJ, English DR. Sun exposure and pterygium of the eye: a dose-response curve. *Am J Ophthalmol*. 1999;128:280-7.
8. Coroneo MT. Pterygium as an early indicator of ultraviolet insolation: a hypothesis. *Br J Ophthalmol*. 1993;77:734-9.
9. Kwok LS, Coroneo MT. A model for pterygium formation. *Cornea* 1994;13:219-24.
10. Bloom AH, Perry HD, Donnenfeld ED, Pinchoff BS, Solomon R. Childhood onset of pterygia in twins. *Eye Contact Lens*. 2005;31:279-80.
11. Tan DT, Tang WY, Liu YP, Goh HS, Smith DR. Apoptosis and apoptosis related gene expression in normal conjunctiva and pterygium. *Br J Ophthalmol*. 2000;84:212-6.
12. Di Girolamo N, Wakefield D, Coroneo MT. UVB-mediated induction of cytokines and growth factors in pterygium epithelial cells involves cell surface receptors and intracellular signaling. *Invest Ophthalmol Vis Sci*. 2006;47:2430-7.

13. Lee DH, Cho HJ, Kim JT, Choi JS, Joo CK. Expression of vascular endothelial growth factor and inducible nitric oxide synthase in pterygia. *Cornea*. 2001;20:738-42.
14. Beden U, Irkeç M, Orhan D, Orhan M. The roles of T-lymphocyte subpopulations (CD4 and CD8), intercellular adhesion molecule-1 (ICAM-1), HLA-DR receptor, and mast cells in etiopathogenesis of pterygium. *Ocul Immunol Inflamm*. 2003;11:115-22.
15. Detorakis ET, Sourvinos G, Spandidos DA. Detection of herpes simplex virus and human papilloma virus in ophthalmic pterygium. *Cornea*. 2001;20:164-7.
16. Suschek CV, Krischel V, Bruch-Gerharz D, et al. Nitric oxide fully protects against UVA-induced apoptosis in tight correlation with Bcl-2 up-regulation. *J Biol Chem*. 1999;274:6130-7.
17. Billiar TR. Nitric oxide. Novel biology with clinical relevance. *Ann Surg*. 1995;221:339-49.
18. Ozdemir G, Inanc F, Kilinc M. Investigation of nitric oxide in pterygium. *Can J Ophthalmol*. 2005;40:743-6.
19. Lee DH, Cho HJ, Kim JT, Choi JS, Joo CK. Expression of vascular endothelial growth factor and inducible nitric oxide synthase in pterygia. *Cornea*. 2001;20:738-42.
20. Tsai YY, Chang KC, Lin CL, et al. p53 Expression in pterygium by immunohisto-chemical analysis: a series report of 127 cases and review of the literature. *Cornea*. 2005;24:583-6.
21. Piras F, Moore PS, Ugalde J, Perra MT, Scarpa A, Sirigu P. Detection of human papillomavirus DNA in pterygia from different geographical regions. *Br J Ophthalmol*. 2003;87:864-6.
22. Dushku N, Reid TW. P53 expression in altered limbal basal cells of pingueculae, pterygia, and limbal tumors. *Curr Eye Res*. 1997;16:1179-92.
23. Bredt DS, Snyder SH. Isolation of nitric oxide synthase, a calmodulin-requiring enzyme. *Proc Natl Acad Sci U S A*. 1990;87:682-5.
24. Toda N, Nakanishi-Toda M. Nitric oxide: ocular blood flow, glaucoma, and diabetic retinopathy. *Prog Retin Eye Res*. 2007;26:205-38.
25. Xu W, Liu LZ, Loizidou M, Ahmed M, Charles IG. The role of nitric oxide in cancer. *Cell Res*. 2002;12:311-20.
26. Li C, Hu Z, Liu Z, et al. Polymorphisms of the neuronal and inducible nitric oxide synthase genes and the risk of cutaneous melanoma: a case-control study. *Cancer*. 2007;109:1570-8.
27. Wink DA, Miranda KM, Espey MG, et al. Mechanisms of the antioxidant effects of nitric oxide. *Antioxid Redox Signal*. 2001;3:203-13.
28. Benz D, Cadet P, Mantione K, Zhu W, Stefano G. Tonal nitric oxide and health--a free radical and a scavenger of free radicals. *Med Sci Monit*. 2002;8:1-4.
29. Opländer C, Cortese MM, Korth HG, et al. The impact of nitrite and antioxidants on ultraviolet-A-induced cell death of human skin fibroblasts. *Free Radic Biol Med*. 2007;43:818-29.
30. Peponis V, Bonovas S, Kapranou A, et al. Conjunctival and tear film changes after vitamin C and E administration in non-insulin dependent diabetes mellitus. *Med Sci Monit*. 2004;10:213-17.