



# Comparative Results of Viscotrabeculotomy and Classical Trabeculotomy in Congenital Glaucoma in a Longer-Term Follow-Up

## Konjenital Glokomlu Olgularda Viskotrabeülotomi ve Klasik Trabeülotomi Cerrahisinin Uzun Dönem Karşılaştırmalı Sonuçları

Nevbahar Tamçelik, Eray Atalay\*, Selim Bölükbaşı\*\*, Erdoğan Cicik, Olgu Çapar

İstanbul University Cerrahpaşa Medical School, Department of Eye Diseases, İstanbul, Turkey

\*Kars State Hospital, Kars, Turkey

\*\*Okmeydanı Training and Research Hospital, İstanbul, Turkey

### Summary

**Purpose:** To evaluate the results of previously described viscotrabeculotomy technique and to compare them with those of conventional trabeculotomy in longer-term follow-up.

**Material and Method:** This retrospective study included the eyes of 64 patients who underwent either viscotrabeculotomy (group 1) or conventional trabeculotomy (group 2) between February 1992 and April 2011. Group 1 consisted of 58 eyes of 34 patients who underwent viscotrabeculotomy surgery and group 2 consisted of 51 eyes of 30 patients who underwent conventional trabeculotomy. 3 patients (5 eyes) in group 1 and 2 patients (3 eyes) in group 2 left the follow-up for some reasons. At the last visit, group 1 comprised 53 eyes of 31 patients and group 2 comprised 48 eyes of 28 patients. Outcome measures were intraocular pressure (IOP), anti-glaucomatous medications, horizontal corneal diameter, and success rate.

**Results:** Success rates in group 1 at 12, 36, 60, 72, 96, 120 months, and at the last visit were 93.10%, 91.30%, 89.30%, 87.00%, 84.90%, 83.00%, and 83.00%, respectively. The success rates in group 2 at the above-mentioned follow-up visits were 72.50%, 68.60%, 68.60%, 66.10%, 66.00%, 64.50%, and 62.50%, respectively. The success rate in group 1 was statistically significantly higher than in group 2 at the last visit ( $p=0.027$ ). IOP and anti-glaucomatous medications at each follow-up examination were lower in group 1 compared to group 2, and these differences were with statistical significance (for each,  $p<0.05$ ). Horizontal corneal diameters did not differ between the two groups in the postoperative follow-up.

**Discussion:** Viscotrabeculotomy has been found safer and more effective than classical trabeculotomy in longer-term evaluation. Viscodissection of the trabecular meshwork, viscodilation of the Schlemm's canal, keeping away the lips of trabeculotomy incision, and possibly prevention of postoperative hemorrhage and fibroblastic proliferation by means of high-viscosity sodium hyaluronate are the possible factors that play an important role in the overall success of this procedure. (*Turk J Ophthalmol* 2013; 43: 380-4)

**Key Words:** Congenital glaucoma, infantile glaucoma, developmental glaucoma, viscotrabeculotomy, trabeculotomy, viscoelastics

### Özet

**Amaç:** Daha önce tanımlanan viskotrabeülotomi tekniğinin daha uzun dönem sonuçlarını değerlendirmek ve konvansiyonel trabeülotomi ile karşılaştırmak.

**Gereç ve Yöntem:** Bu retrospektif çalışmaya Şubat 1992 ile Nisan 2011 tarihleri arasında viskotrabeülotomi (grup 1) ve geleneksel trabeülotomi (grup 2) ameliyatı uygulanan 64 hasta dahil edildi. Grup 1 viskotrabeülotomi uygulanan 34 hastanın 58 gözünden, grup 2 konvansiyonel trabeülotomi uygulanan 30 hastanın 51 gözünden oluşmaktadır. Grup 1'deki 3 hasta (5 göz) ve grup 2'deki 2 hasta (3 göz) çeşitli sebeplerden dolayı takiplerini bıraktı. Son vizitte, grup 1; 31 hastanın 53 gözünden, grup 2; 28 hastanın 48 gözünden oluşmaktaydı. Sonuç ölçütleri göz içi basıncı, anti-glokom ilaçları, horizontal kornea çapı ve başarı oranı olarak belirlendi.

**Sonuçlar:** Grup 1'in başarı oranları 12, 36, 60, 72, 96, 120. ayda ve son vizitte sırasıyla %93,10, %91,30, %89,30, %87,00, %84,90, %83,00 ve %83,00 idi. Aynı takip aralıklarında grup 2'nin başarı oranları sırasıyla %72,50, %68,60, %68,60, %66,10, %66,00, %64,50 ve %62,50 idi. Son vizitte grup 1'in başarı oranı grup 2'ye göre istatistiksel olarak anlamlı derecede yüksek bulunmuştur ( $p=0,027$ ). Her ayrı izlem muayenesinde GİB ve anti-glokom ilaçları kullanımı grup 1'de grup 2'ye göre istatistiksel olarak anlamlı derecede düşük bulundu ( $p<0,05$ , her biri). Yatay korneal çapları açısından ameliyat sonrası takiplerde iki grup arasında anlamlı fark bulunamadı.

**Tartışma:** Viskotrabeülotominin uzun vadede de klasik trabeülotomiye göre daha güvenli ve daha etkili olduğu bulunmuştur. Viskotrabeülotomide kullanılan yüksek viskoziteli sodyum hyalüronat; trabeülüler ağda viskodiseksiyon ve Schlemm kanalında viskodilatasyon oluşturarak ve ayrıca trabeülotomi insizyon dudaklarının birbirinden bir müddet uzak tutulmasını sağlayarak, postoperatif kanama ve fibroblastik proliferasyonu önlemesi sonucunda bu ameliyatın genel başarısı artmaktadır. (*Turk J Ophthalmol* 2013; 43: 380-4)

**Anahtar Kelimeler:** Konjenital glokom, infantile glokom, gelişimsel glokom, viskotrabeülotomi, trabeülotomi, viskoelastik

**Address for Correspondence/Yazışma Adresi:** Nevbahar Tamçelik MD, İstanbul University Cerrahpaşa Medical School, Department of Eye Diseases, İstanbul, Turkey

Phone.: +90 212 215 51 80 E-mail: nevbahartamcelik@gmail.com **Received/Geliş Tarihi:** 16.06.2013 **Accepted/Kabul Tarihi:** 09.01.2014

## Introduction

Congenital glaucoma is one of the major causes of childhood blindness where consanguineous marriages are more common. It manifests itself during the first years of life with elevated intraocular pressure (IOP), globe enlargement (buphthalmus), corneal edema, Haab's striae, optic nerve cupping and atrophy.<sup>1</sup> Early detection and management are crucial to prevent irreversible optic nerve damage and further complications of this disabling disease. Treatment is surgical, which involves improving the facility of outflow by incising or cleaving the abnormal trabecular meshwork.<sup>2-7</sup> Besides the conventional procedures which include goniotomy, trabeculotomy ab externo and trabeculectomy, many new surgical procedures have been developed as safer and probably more efficacious alternatives.<sup>8-12</sup> With the advent of viscoelastic materials, Tamçelik have previously described the viscotrabeculotomy technique which incorporates viscodissection and viscodilation procedures to the conventional trabeculotomy. The results of this technique in comparison with conventional trabeculotomy during a mean follow-up period of 60 months have been previously published.<sup>3</sup>

The purpose of this study was to evaluate the results of viscotrabeculotomy and to compare them with those of conventional trabeculotomy in longer-term follow-up. Practically, this study is the continuation of the previously published one, thus herein we report the longer-term results.

## Material and Methods

### Patient Selection

The charts of 64 patients who underwent either viscotrabeculotomy (group 1) or conventional trabeculotomy (group 2) between February 1992 and April 2011 were retrospectively reviewed. All patients were followed up for at least 10 years. Group 1 consisted of 58 eyes of 34 patients who underwent viscotrabeculotomy surgery and group 2 consisted of 51 eyes of 30 patients who underwent conventional trabeculotomy. 3 patients (5 eyes) in group 1 and 2 patients (3 eyes) in group 2 left the follow-up for some reasons. At the last visit, group 1 comprised 53 eyes of 31 patients and group 2 comprised 48 eyes of 28 patients. Exclusion criteria were as follows: history of previous surgery, secondary glaucoma, Axenfeld-Rieger syndrome, aniridia, Sturge-Weber syndrome.

The diagnosis of congenital glaucoma was established in the operating room under inhalational anesthesia using 1% halothane. IOP was measured using a Perkins hand-held applanation tonometer or tonopen in the early phase of anesthesia. Other pre- and postoperative examinations included biomicroscopy, measurement of horizontal corneal diameter, and fundoscopy. Age, sex, family history, main presenting symptom, anti-glaucomatous medications, time of surgery, follow-up time, intra- and postoperative complications, and success rates were also recorded.

### Surgical Technique

Classical trabeculotomy was performed using a standardized technique similar to that described by Allen and Burian.<sup>8</sup> In viscotrabeculotomy, a limbus-based conjunctival flap and a triangular-shaped scleral flap were prepared in the upper temporal quadrant (Figure 1-A). Radial incision was performed until scleral spur fibers were observed and Schlemm's canal was exposed (Figure 1-B). Schlemm's canal was cannulated approximately 5 millimeters on either side using the Grieshaber cannula, and a high-viscosity sodium hyaluronate (Healon GV®, Abbott Medical Optics, Abbott Park, Illinois, USA) was injected into the Schlemm's canal while drawing the cannula out (Figure 1-C). An angled Harms trabeculotome was passed into the canal; the tip of the probe was gently rotated into the anterior chamber and pulled back toward the incision (Figure 1-D). The probe was removed, and the procedure was repeated in the opposite side with the paired trabeculotome. Sodium hyaluronate (Healon) was injected into the anterior chamber, if a shallow anterior chamber developed. Then, a small amount of high-viscosity sodium hyaluronate was injected to prevent adhesion of incision lips. The triangular scleral flap was sutured with one 10/0 nylon suture, and the conjunctiva was closed with an absorbable 8-0 vicryl suture (Figure 1-E). At the end of the procedure, one drop of antibiotic-corticosteroid preparation was instilled into the lower conjunctival sac, and a patch was applied on the eye.

Postoperatively, topical corticosteroids and cycloplegics were administered until there was a complete resolution of post-operative inflammation. Topical antibiotics were administered five times a day, tapered gradually over a 4-week period. In group 1,  $\beta$ -blockers were used twice for 4 days to control transient IOP elevation. The patients were examined twice during the first week, weekly during the first month, monthly during the first year, and then, every 3 months.

Complete surgical success was determined by an IOP <18 mm Hg under general anesthesia without medication or resurgery, with no progression of disc cupping or corneal diameter, and with no devastating visual complications. Qualified success was defined as an IOP <18 mm Hg with anti-glaucomatous medication or transient ocular hypotony without visual loss. Failure was defined as IOP  $\geq$ 18 mm Hg in patients with medication, resurgery, or sight-threatening complications.

### Statistical Analysis

Collected data were recorded into a Microsoft Excel Datasheet and transferred to SPSS version 21.0 by IBM (SPSS Inc, Chicago, Illinois, USA) for statistical analysis. Mean values of the two groups were analyzed using student's t-test. A p-value < 0.05 was considered statistically significant.

## Results

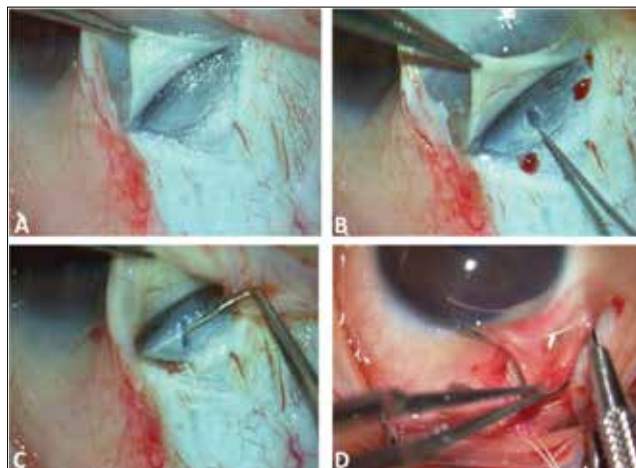
The demographic information of the two groups is presented in Table 1. The proportional distribution of sex was not statistically different between the groups (p=0.51). 29/53 (54.7%) eyes in group 1 and 30/48 (62.5%) eyes in group 2 were diagnosed as isolated trabeculodysgenesis by using Hoskins

and Schaffer classification. Iridotrabeculodysgenesis without abnormal vessels was present in 24 eyes (45.2%) in group 1 and in 18 eyes (41.6%) in group 2. The number of patients who underwent bilateral glaucoma surgery in group 1 and 2 was 22 and 20, respectively (Table 1).

Table 2 shows the mean IOP, anti-glaucomatous medications, and horizontal corneal diameter of the two groups in the pre-operative setting and in the post-operative setting at 12, 36, 60, 72, 96, 120 months, and at the last visit. Success rates at the above-mentioned follow-up evaluations are also reported in Table 2. The differences between the two groups regarding mean pre-operative IOP, anti-glaucomatous medications, and horizontal corneal diameters were not statistically significant (for each,  $p > 0.05$ ). IOP and anti-glaucomatous medications at each follow-up examination were lower in group 1 compared to group 2, and these differences were statistically significant (for each,  $p < 0.05$ ). Horizontal corneal diameters did not differ between the two groups in the postoperative follow-up.

Success rates in group 1 at 12, 36, 60, 72, 96, 120 months, and at the last visit were 93.10%, 91.30%, 89.30%, 87.00%, 84.90%, 83.00%, and 83.00%, respectively. The success rates in

group 2 at the above-mentioned follow-up visits were 72.50%, 68.60%, 68.60%, 66.10%, 66.00%, 64.50%, and 62.50%, respectively. The success rate in group 1 was statistically significantly higher than in group 2 at the last visit ( $p = 0.027$ ). To control IOP, 13 eyes in group 1 and 20 eyes in group 2 required anti-glaucomatous medications, i.e. b-blockers, topical carbonic anhydrase inhibitors, and prostaglandin analogues. Additional surgery was performed in 8 eyes in group 1 and in 15 eyes in group 2.



**Figure 1.** A limbus-based conjunctival flap and a triangular-shaped scleral flap was prepared in the upper temporal quadrant (A). Radial incision was performed until scleral spur fibers were observed and Schlemm's canal was exposed (B). Schlemm's canal was cannulated approximately 5 millimeters on either side using the Grieshaber cannula, and a high-viscosity sodium hyaluronate was injected into the Schlemm's canal while drawing the cannula out (C). An angled Harms trabeculotome was passed into the canal; the tip of the probe was gently rotated into the anterior chamber and pulled back toward the incision (D). The triangular scleral flap was sutured with one 10/0 nylon suture, and the conjunctiva was closed with an absorbable 8-0 vicryl suture (E)

	<b>Group 1</b>	<b>Group 2</b>
Number of patients	31	28
Number of eyes	53	48
Mean (SD) age (months)	4.5 (4.0)	4.3 (3.9)
Gender (m/f)	17/14	15/13
Bilateral glaucoma	22/31 (70.9%)	20/28 (71.4%)

	<b>Group 1 (n=53 eyes)</b>							
	<b>Pre op.</b>	<b>12 months</b>	<b>36 months</b>	<b>60 months</b>	<b>72 months</b>	<b>96 months</b>	<b>120 months</b>	<b>LV</b>
Mean (SD) IOP (mmHg)	30.6 (5.7)	16.0 (3.0)	16.1 (3.0)	16.2 (2.9)	16.4 (2.8)	16.5 (3.1)	16.5 (3.5)	16.9 (3.0)
Mean (SD) AM	2.2 (0.8)	0.2 (0.5)	0.3 (0.4)	0.3 (0.4)	0.6 (0.3)	0.8 (0.4)	0.8 (0.5)	0.9 (0.5)
Mean (SD) HCD (mm)	14.2 (0.9)	13.8 (0.8)	13.9 (0.8)	13.9 (0.8)	13.8 (0.9)	13.9 (0.9)	13.9 (0.7)	13.9 (0.8)
Success rate	-	93.10%	91.30%	89.30%	87.00%	84.90%	83.00%	83.00%
Mean (SD) follow-up time (months)	144 (12.8)							
	<b>Group 2 (n=48 eyes)</b>							
Mean (SD) IOP (mmHg)	29.9 (4.9)	17.1 (3.1)	17.3 (2.9)	17.3 (2.8)	17.2 (2.9)	17.5 (3.1)	17.4 (3.5)	17.6 (3.2)
Mean (SD) AM	2.4 (0.6)	0.4 (0.6)	0.5 (0.6)	0.5 (0.5)	0.7 (0.4)	0.9 (0.5)	1.0 (0.6)	1.2 (0.8)
Mean (SD) HCD (mm)	14.1 (1.0)	13.9 (0.8)	13.9 (0.8)	13.8 (0.8)	13.9 (0.7)	13.9 (0.6)	13.9 (0.7)	13.8 (0.9)
Success rate	-	72.50%	68.60%	68.60%	66.10%	66.00%	64.50%	62.50%
Mean (SD) follow-up time (months)	145 (15.5)							

IOP: Intraocular pressure; AM: anti-glaucomatous medications; HCD: horizontal corneal diameter; Preop: preoperative

Iridodialysis with severe bleeding was the only significant complication observed in 1 eye in group 2. Management of this complication required sodium hyaluronate injection into the anterior chamber to stop the bleeding. The most common complication in the early postoperative period was hyphaema in group 2 and transient IOP elevation in group 1, which was treated with anti-glaucomatous medications for a few days.

## Discussion

The management of congenital glaucoma is surgical, and traditional surgery has centered on incising or cleaving the abnormal trabecular meshwork. This can be achieved by incising the meshwork *ab interno* or *ab externo*, with goniotomy or trabeculotomy, respectively.<sup>2-7</sup>

The advantages of goniotomy is not to disturb the conjunctiva if filtering surgery is subsequently needed, but this procedure requires an adequate view of the trabecular meshwork.<sup>13</sup> Up to 50% of the population are reported to have varying degrees of corneal edema, rendering goniotomy technically impossible.<sup>14</sup> Therefore, it was restricted to those patients with a clearer cornea, and the surgeon should have sufficient experience. The technique used in viscogoniotomy provides less hemorrhage by viscoelastics during trabecular meshwork incision, and this is the reason why it is superior to classical goniotomy.<sup>2</sup>

Trabeculotomy *ab externo* is an alternative surgical technique that is possible even in the presence of severe corneal edema. The advantages of trabeculotomy *ab externo* over goniotomy have been reported by Luntz.<sup>15</sup> In addition, a higher success rate with trabeculotomy has been reported as the initial procedure compared with goniotomy.<sup>16</sup> The only disadvantage of trabeculotomy is that the Schlemm's canal may not be found in 11-15% of procedures. This may be caused by surgical inexperience, abnormal anatomy or hypoplasia of the canal.<sup>13,17</sup> Nevertheless, most surgeons currently favor trabeculotomy because of their familiarity with the surgery gained by trabeculectomy. We preferred to perform trabeculotomy *ab externo* as the initial surgical procedure because all of the patients had significant corneal edema.

In recent years, viscoelastic materials have become a predominant element in the performance of ocular surgery. Viscoelastic materials are indispensable in the prevention of damage to ocular tissue and are also used as multipurpose tools in all surgical phases.<sup>18,19</sup> The term of viscosurgery was first introduced by Balazs, and one of the aims of this procedure was to accomplish procedures and maneuvers that require the performance of space tactics.<sup>20</sup> In addition, viscoelastics separate or stabilize tissues, stop bleeding, and protect the tissues against undesired damage.<sup>18,21-23</sup> The disadvantage of viscoelastic materials is that they are not metabolized in the eye and will leave the anterior chamber through the trabeculum. Clearance of viscoelastic materials depends on the volume injected, the concentration and viscosity of the material, and the amount left in the anterior chamber. When left in the anterior chamber or partly removed at the end of

surgery, they can cause a temporary IOP elevation.<sup>24</sup> In our study, a small amount of high-viscosity sodium hyaluronate was injected into the Schlemm's canal on either side to prevent late bleeding and adhesion of the incision lips.<sup>25</sup> Injection of viscoelastics into the Schlemm's canal by the Grieshaber cannula provides a more convenient and more comfortable cannulation.<sup>26</sup> Viscoelastic materials remain in the canal for 4-6 days, prevent the collapse of the Schlemm's canal, and create a barrier to the migration of fibrinogen released by the ciliary body during surgery.<sup>27</sup> As a result, polymerization of the fibrinogen to fibrin in the lake and Schlemm's canal was almost eliminated and removed the stimulus for fibroblastic proliferation. Moreover, prevention of adhesion of the incision lips or anterior chamber shallowing with sodium hyaluronate may decrease postoperative inflammation and limit the wound healing process and cicatrization. Otherwise, the meshwork tissues may gradually overgrow the trabeculotomy site, and this may explain some of the declining success with time. The only disadvantage of viscotrabeculotomy may be transient IOP elevation that can be controlled with anti-glaucomatous medications in a few days.

The success rates published in the literature for primary trabeculotomy have been reported ranging between 50% and 90%.<sup>9,13,15-17,28</sup> However, the ethnic factor, the age of patients at onset of glaucoma, types of abnormalities, individual varieties, and follow-up time may influence the success rates. To increase the success rate of this procedure in congenital glaucoma, several modifications were performed.<sup>13,14,29-31</sup> Elder reported the success rate of 93.5% for combined trabeculotomy-trabeculectomy after 24 months of follow-up.<sup>13</sup> In another study by Mullaney et al,<sup>29</sup> the success rate of combined trabeculotomy and trabeculectomy as an initial procedure in uncomplicated congenital glaucoma was found to be 78% after a mean follow-up period of 304 days. The success rate of trabeculotomy performed with newly designed probes by Filous and Brunova was 87%.<sup>30</sup> In the present study, we performed viscotrabeculotomy in the management of congenital glaucoma and compared the outcomes with classical trabeculotomy. The success rates of classical trabeculotomy and viscotrabeculotomy in the previously reported study were 68.6% and 91.3%, respectively.<sup>3</sup> In the present study, the last-visit success rates for viscotrabeculotomy and classical trabeculotomy were 83.0% and 62.5%, respectively (Table 2). This may be explained by prevention of postoperative hemorrhage or fibroblastic proliferation, non-traumatic cannulation of the Schlemm's canal after viscodilation and viscodissection with viscoelastic material, keeping away the lips of the trabeculotomy incision, and prevention of anterior chamber shallowing, which play important roles in decreasing the anterior chamber inflammation and retarding the wound-healing process.

Transient IOP elevation was the most common early postoperative complication in group 1. The incidence of hyphaema in group 1 was only 6.8% but 27.4% in group 2 in the early postoperative period. These low rates of hyphaema

in the viscotrabeculotomy group may only be explained by using viscoelastic materials in group 1. Viscoelastic materials may prevent bleeding because they form a physical barrier and concentrate coagulation factors at the site of bleeding to achieve hemostasis. Prevention of bleeding from incision lips may therefore decrease the inflammation and risk of adhesion of incision lips, and also may increase the success rate. In addition, viscomaterials may facilitate cannulation of Schlemm's canal by maintaining a stable and larger canal and provide a safe and convenient tissue incision.

In conclusion, also in longer-term follow-up, viscotrabeculotomy has been found safer and more effective than classical trabeculotomy. Intra- and post-operative serious complications are very rare. Viscodissection of the trabecular meshwork, viscodilation of the Schlemm's canal, keeping away the lips of trabeculotomy incision, and possibly prevention of postoperative hemorrhage and fibroblastic proliferation by means of high-viscosity sodium hyaluronate are the possible factors that play an important role in the overall success of this procedure.

## References

- Walton DS. Congenital glaucoma. Traboulsi EI, ed. Genetic Diseases of the Eye. New York: Oxford University Press. 1998;177-82.
- Tamcelik N, Ozkiris A. A comparison of viscogoniotomy with classical goniotomy in Turkish patients. *Jpn J Ophthalmol*. 2004;48:404-7.
- Tamcelik N, Ozkiris A. Long-term results of viscotrabeculotomy in congenital glaucoma: comparison to classical trabeculotomy. *Br J Ophthalmol*. 2008 Jan;92:36-9.
- Ozkiris A, Tamcelik N. Long-term results of trabeculectomy with different concentrations of mitomycin C in refractory developmental glaucoma. *J Pediatr Ophthalmol Strabismus*. 2005;42:97-102.
- Khaw PT, Freedman S, Gandolfi S. Management of congenital glaucoma. *J Glaucoma* 1999;8:81-85.
- Turacli ME, Aktan G, Idil A. Medical and surgical aspects of congenital glaucoma. *Acta Ophthalmol Scand*. 1995;73:261-3.
- Tamçelik N, Sarici AM, Yetik H, Ozkök A, Ozkiris A. A novel surgical technique to prevent postoperative Ahmed valve tube exposure through conjunctiva: tenon advancement and duplication. *Ophthalmic Surg Lasers Imaging*. 2010;41:370-4.
- Mandal AK, Chakrabarti D. Update on congenital glaucoma. *Indian J Ophthalmol*. 2011;59:S148-57.
- Mendicino ME, Lynch MG, Drack A, Beck AD, et al. Long-term surgical and visual outcomes in primary congenital glaucoma: 360 degrees trabeculotomy versus goniotomy. *J AAPOS*. 2000;4:205-10.
- Sarkisian SR. An illuminated microcatheter for 360-degree trabeculotomy [corrected] in congenital glaucoma: a retrospective case series. *Jr J AAPOS*. 2010;14:412-6.
- Girkin CA, Marchase N, Cogen MS. Circumferential trabeculotomy with an illuminated microcatheter in congenital glaucomas. *J Glaucoma*. 2012;21:160-3.
- Zhang X, Du S, Fan Q, Peng S, Yu M, Ge J. Long-term surgical outcomes of primary congenital glaucoma in China. *Clinics (Sao Paulo)*. 2009;64:543-51.
- Elder MJ. Congenital glaucoma in West Bank and Gaza Strip. *Br J Ophthalmol*. 1993;77:413-6.
- O'Connor G. Combined trabeculotomy-trabeculectomy for congenital glaucoma. *Br J Ophthalmol*. 1994;78:735.
- Luntz MH. The advantages of trabeculotomy over goniotomy. *J Pediatr Ophthalmol Strabismus*. 1984;21:150-3.
- McPherson SD Jr, Berry DP. Goniotomy vs external trabeculotomy for developmental glaucoma. *Am J Ophthalmol*. 1983;95:427-31.
- Harms H, Dannheim R. Epicritical consideration of 300 cases of trabeculotomy ab externo. *Trans Ophthalmol Soc UK*. 1970;89:491-9.
- Silver FH, LiBrizzi J, Benedetto D. Use of viscoelastic solutions in ophthalmology: a review of physical properties and long-term effects. *J Long Term Eff Med Implants*. 1992;2:49-66.
- Goa KL, Benfield P. Hyaluronic acid. A review of its pharmacology and use as a surgical aid in ophthalmology, and its therapeutic potential in joint disease and wound healing. *Drugs*. 1994;47:536-66.
- Balazs EA, Denlinger JL. Clinical uses of hyaluronan. *Ciba Found Symp*. 1989;143:265-75.
- Maar N, Graebe A, Schild G, et al. Influence of viscoelastic substances used in cataract surgery on corneal metabolism and endothelial morphology: comparison of Healon and Viscoat. *J Cataract Refract Surg*. 2001;27:1756-61.
- Wild GJ, Kent AR, Peng Q. Dilation of Schlemm's canal in viscocanalostomy: comparison of 2 viscoelastic substances. *J Cataract Refract Surg*. 2001;27:1294-7.
- McDermott ML, Hazlett LD, Barrett RP, et al. Viscoelastic adherence to corneal endothelium following phacoemulsification. *J Cataract Refract Surg*. 1998;24:678-83.
- Rainer G, Menapace R, Findl O, et al. Intraocular pressure after small incision cataract surgery with Healon5 and Viscoat. *J Cataract Refract Surg*. 2000;26:271-6.
- Yang HK, Park KH. Clinical outcomes after Ahmed valve implantation in refractory paediatric glaucoma. *Eye (Lond)*. 2009;23:1427-35.
- Papadopoulos M, Khaw PT. Advances in the management of paediatric glaucoma. *Eye (Lond)*. 2007;21:1319-25.
- Johnson DH, Johnson M. How does nonpenetrating glaucoma surgery work? Aqueous outflow resistance and glaucoma surgery. *J Glaucoma*. 2001;10:55-67.
- Hoskins HD, Shaffer RN, Hetherington J. Goniotomy vs trabeculotomy. *J Pediatr Ophthalmol Strabismus*. 1984;21:153-8.
- Mullaney PB, Selleck C, Al-Awad A, et al. Combined trabeculotomy and trabeculectomy as an initial procedure in uncomplicated congenital glaucoma. *Arch Ophthalmol*. 1999;117:457-60.
- Filous A, Brunova B. Results of the modified trabeculotomy in the treatment of primary congenital glaucoma. *J AAPOS* 2002;6:182-6.
- Tamcelik N, Ozkiris A, Sarici AM. Long-term results of combined viscotrabeculotomy-trabeculectomy in refractory developmental glaucoma. *Eye (Lond)*. 2010;24:613-8.