



Evaluation of Choroidal Vascular Index in Amblyopic Patients

Onur Furundaoturan, Cumali Değirmenci, Cezmi Akkın, Elif Demirkılınc Biler, Önder Üretmen, Serhad Nalçacı, Filiz Afrashi

Ege University Faculty of Medicine, Department of Ophthalmology, İzmir, Turkey

Abstract

Objectives: To compare subfoveal choroidal thickness (SFCT) and choroidal vascular index (CVI) in patients with hyperopic refractive and strabismic amblyopia and healthy subjects.

Materials and Methods: The study included 17 patients with strabismic amblyopia (Group 1), 29 patients with hyperopic refractive amblyopia (Group 2), and 16 eyes of 16 healthy volunteers (Group 3). Best corrected visual acuity was noted in all patients and volunteers. In addition to detailed anterior and posterior segment examinations, macular images were obtained by enhanced-depth imaging mode of optical coherence tomography (OCT). SFCT measurements were made from these images and CVI was calculated using the Image J program.

Results: No significant difference was found between the groups in terms of age, gender, and intraocular pressure ($p=0.27$, 0.64 , and 0.85 , respectively). Mean BCVAs in Group 1 were 0.57 ± 0.16 (0.3-0.8) in the amblyopic eyes, 0.94 ± 0.08 (0.8-1.0) in the fellow eyes, and in Group 2 were 0.61 ± 0.17 (0.2-0.8) in amblyopic eyes, 0.92 ± 0.1 (0.8-1.0) in fellow eyes. BCVA in Group 3 was 1.0 ± 0 (1.0-1.0). Mean SFCT of the amblyopic eyes in Groups 1 and 2 was 341.50 ± 60.4 (277-481) and 370.06 ± 65.3 (247-462), respectively, and in the healthy eyes of Groups 1 and 2 and Group 3 was 321.92 ± 68.26 (251-440), 330.35 ± 74.00 (194-502), and 327.62 ± 40.79 (238-385), respectively. SFCT was significantly greater in the amblyopic eyes of Group 2 compared to Group 3 ($p=0.01$). Mean CVI was 0.681 ± 0.032 (0.642-0.736) in the amblyopic eyes and 0.685 ± 0.054 (0.587-0.788) in the fellow eyes of Group 1 patients; 0.664 ± 0.033 (0.592-0.719) in the amblyopic eye and 0.707 ± 0.039 (0.625-0.779) in the fellow eye in Group 2 patients; and 0.689 ± 0.031 (0.612-0.748) in Group 3 patients. CVI was significantly lower in the amblyopic eyes of Group 2 compared with fellow eyes ($p=0.02$) and Group 3 ($p=0.025$).

Conclusion: Morphological changes may be seen in the choroid in amblyopic eyes. We observed that the choroidal stromal component is increased in hyperopic amblyopic patients especially.

Keywords: Amblyopia, choroidal thickness, choroidal vascularity index

Address for Correspondence: Onur Furundaoturan, Ege University Faculty of Medicine, Department of Ophthalmology, İzmir, Turkey

E-mail: onurfurundaoturan@hotmail.com **ORCID-ID:** orcid.org/0000-0001-6929-6645

Received: 25.12.2020 **Accepted:** 26.05.2021

Cite this article as: Furundaoturan O, Değirmenci C, Akkın C, Demirkılınc Biler E, Üretmen Ö, Nalçacı S, Afrashi F. Evaluation of Choroidal Vascular Index in Amblyopic Patients. Turk J Ophthalmol 2022;52:168-173

©Copyright 2022 by Turkish Ophthalmological Association
Turkish Journal of Ophthalmology, published by Galenos Publishing House.

Introduction

Amblyopia is a pathology caused by abnormal binocular image or visual deprivation that manifests clinically with unilateral or bilateral reduction in best corrected visual acuity (BCVA).^{1,2} Its global prevalence varies between 2% and 4%.^{2,3} It is considered the most important cause of unilateral visual impairment, especially in children, and can be prevented with treatment if detected at an early age.^{2,4}

The two most common subtypes of amblyopia are strabismus and anisometropia, which also constitute its main causes. Amblyopia may occur as a result of strabismus and anisometropia alone or the coexistence of these two pathologies.^{1,3,4,5}

Various defects in the visual cortex and cell degradation in the lateral geniculate nucleus are thought to play a role in the development of amblyopia, and it is suggested that inhibition by the fellow eye occurs at various stages of visual development.⁶ In addition, structural anomalies of the optic radiation axons and extrastriate areas have been detected in amblyopic patients; however, studies on this subject are ongoing.^{7,8}

The choroid, which has important roles in ocular physiology and homeostasis such as temperature control, nutrition, and waste removal, may also play a role in the pathophysiology of amblyopia. It is believed that the choroid influences the formation of a clear retinal image through its ability to change in thickness and volume.⁹ Recent studies have shown that changes in subfoveal choroidal thickness (SFCT), which can help adjust retinal image clarity, can also occur over short periods of time.¹⁰ SFCT is determined using optical coherence tomography (OCT) and its enhanced-depth imaging (EDI) mode. In many studies using EDI-OCT, retinal thickness and SFCT were reported to be higher in amblyopic eyes than in both the patients' fellow eyes and normal control groups.^{11,12}

The choroidal vascular index (CVI), a parameter recently used in the evaluation of the choroidal vasculature, is the ratio of the vascular lumen to the entire choroidal area. It can provide information about the pathophysiological changes that occur in the choroid, which almost certainly has a role in amblyopia.^{13,14}

This study aimed to compare the SFCT and CVI values of patients with hypermetropic refractive and strabismic amblyopia with those of healthy eyes.

Materials and Methods

This study was designed as a prospective, case-control study and included amblyopic patients seen in the strabismus unit of the Ege University Faculty of Medicine Hospital and healthy volunteers examined in the outpatient clinic. Approval was obtained from the medical research ethics committee of the university in which the study was conducted, and an informed

consent form was signed by the parent or legal guardian of each participant.

The study included 17 eyes of 17 patients with strabismic amblyopia who were currently receiving occlusion therapy (Group 1), 29 eyes of 29 patients with hyperopic anisometropic amblyopia (Group 2), and 16 eyes of 16 age- and gender-matched healthy volunteers (Group 3, control group). All patients and controls underwent detailed ophthalmological examination including BCVA measurement, anterior and posterior segment examinations, intraocular pressure measurement (Tonopen, Avia), and cycloplegic refraction (Topcon KR-7000P, Topcon Europe BV, Capelle a/d IJssel, Netherlands). Spherical equivalent was derived from cycloplegic refraction values. In addition, a single subfoveal EDI-OCT (Heidelberg Engineering, Heidelberg, Germany) scan was obtained. As previous studies have shown that the choroid shows diurnal variations, scans were performed between 9:00 AM and 12:00 PM in all patients and by the same researcher.^{15,16} SFCT and CVI were evaluated from EDI-OCT images. From these images, CVI was measured with the binarization method using the Image J program (National Institutes of Health, Bethesda, MD, USA). To calculate CVI, lines were drawn at the RPE-choroidal junction 750 μ m nasal and temporal of the foveal center, after which the area up to the choriocleral junction was selected using the program's polygon drawing tool. As described in the literature, the index was calculated as the proportion of the luminal area to the total choroidal area (Figure 1).^{13,14,17} Measurements based on EDI-OCT were performed by two different researchers and the average of the two measurements was included in the analysis.

Amblyopia was diagnosed as one eye with BCVA lower than 8/10 and at least 2 Snellen lines difference from the fellow eye with normal BCVA. The patients were included in the appropriate group according to the cause of amblyopia. Only patients with hyperopic refractive errors and anisometropic patients with refractive error difference of +2 diopters or greater between the eyes were included in the refractive amblyopia group. Patients with meridial amblyopia and astigmatic amblyopia were excluded.

We also excluded patients who had amblyopia associated with organic causes, a history of ocular surgery, autoimmune-inflammatory diseases that may cause retinal or choroidal involvement or thickness changes, any drug use, high coffee intake or heavy smoking, systemic comorbidity, or inability to cooperate with OCT.^{18,19}

The control group was selected from among patients presenting for routine outpatient visits who had no significant refractive error or manifest deviation, had uncorrected BCVA of 20/20 bilaterally, and were able to cooperate with OCT scans.

Only their right eyes were included in the study to ensure data diversity.

IBM SPSS Statistics version 20.0 (IBM Corp, Armonk, NY, USA) software package was used for statistical analyses. Numerical variables were expressed as mean and standard deviation (minimum-maximum). Mann-Whitney U test was used for intergroup comparisons and chi-square test was used for comparisons of demographic data. P values lower than 0.05 were considered statistically significant.

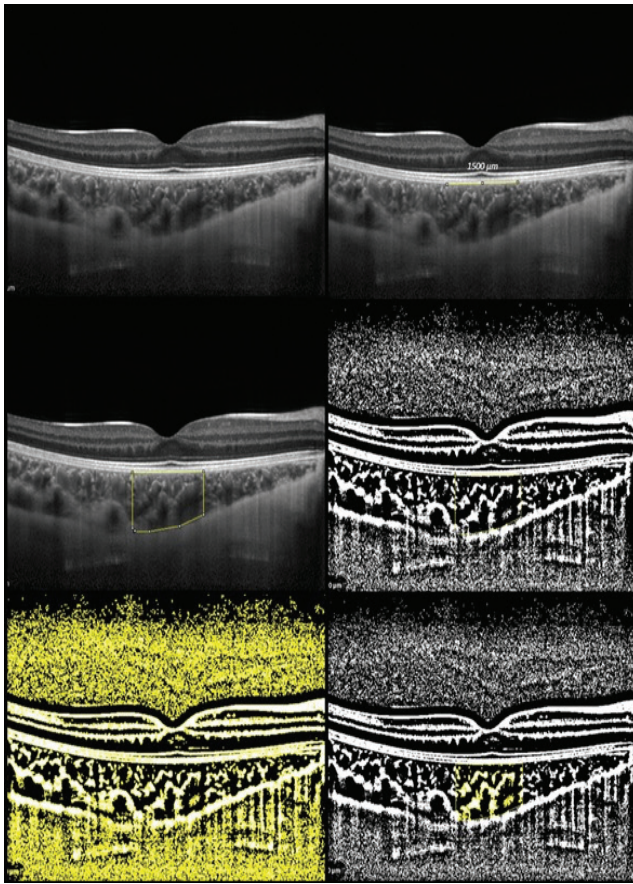


Figure 1. Calculating the choroidal vascular index at 750 μm nasal and temporal of the foveal center by binarization method using Image J software

Results

The study included 46 patients with amblyopia and 16 healthy volunteers. There was no significant difference in age, sex, or intraocular pressure measurements between the groups ($p=0.271$, $p=0.647$, and $p=0.853$, respectively) (Table 1).

Mean BCVA was 0.57 ± 0.16 (range: 0.30-0.80) in Group 1 amblyopic eyes and 0.94 ± 0.07 (range: 0.80-1.00) in Group 1 fellow eyes. In Group 2, mean BCVA was 0.61 ± 0.17 (range: 0.20-0.70) in amblyopic eyes and 0.92 ± 0.10 (range: 0.80-1.00) in fellow eyes. Mean BCVA was 1.00 in Group 3 controls. SFCT was significantly higher and CVI was significantly lower in the amblyopic eyes of Group 2 when compared with these patients' fellow eyes ($p=0.05$ and $p=0.02$, respectively) and Group 3 ($p=0.01$ and $p=0.025$, respectively) (Table 2).

Discussion

Although the cause of amblyopia has not been fully determined, various mechanisms have been suggested as being involved in its pathophysiology, such as cell destruction in the lateral geniculate body and visual stimuli reaching different projections.⁷ Recent advances in imaging technologies have led to a differing view of the pathophysiology of diseases. Thickness changes in the choroid are observed in many diseases, including amblyopia. This study examined the choroidal vasculature in addition to SFCT and showed that CVI was significantly lower in amblyopia, especially cases of hyperopic anisometropic etiology, while the luminal area corresponding to the choroidal vessels did not differ significantly.

With OCT and EDI mode becoming indispensable in ophthalmology practice, detailed examination of the choroid and its layers has become more accessible. The relationship between the choroid and amblyopia, which remains an important problem with still unclear pathophysiology, has also been a subject of research.^{12,17,20,21,22} In a meta-analysis evaluating 17 studies including 768 eyes, SFCT was found to be significantly higher in eyes with refractive amblyopia compared to fellow eyes and the control group, consistent with our study ($p<0.01$).¹² Aygıt et al.²³ analyzed SFCT in 120 eyes with both strabismic and anisometropic amblyopia and determined that SFCT was

Table 1. Demographic data of the patient and control groups

	Group 1 mean ± SD (range)	Group 2 mean ± SD (range)	Control mean ± SD (range)	p value
Number	17	29	16	
Age (years)	9.75±4.24 (4-17)	8.20±1.32 (6-10)	11.35±3.05 (6-17)	0.271
Gender (M/F)	9/8	17/15	10/6	0.647

SD: Standard deviation, M: Male, F: Female

significantly greater in both groups compared to control and fellow eyes. Findings from these studies reveal a relationship between choroidal thickness and strabismic and hyperopic refractive amblyopia. Consistent with the literature, in the present study SFCT values were significantly higher in eyes with hyperopic anisometropic amblyopia. However, there was no significant difference in patients with strabismic amblyopia.

Choroidal thickness is known to be significantly affected by axial length. Choroidal thickness was found to be lower in myopic patients and higher in hyperopic patients compared to healthy volunteers.¹⁹ Since axial length could not be examined in this study, we could not evaluate this.

An important component of the retinal blood supply, the choroid is a dense vascular tissue supported by a loose stroma and has the highest blood flow per unit of tissue in the body.⁹ Therefore, in diseases in which the choroid is involved in the pathophysiology, such as amblyopia, it may be more important to evaluate the subcomponent of the tissue responsible for the increase/decrease rather than simply evaluating a change in thickness. CVI is presented here as data that may be more meaningful and detailed than thickness.^{13,14}

CVI, a new parameter first described by Sonoda et al.,¹⁷ is based on binarization and provides information about the vascular/luminal and stromal components of the choroid.^{24,25} In another study, it was reported that with aging, the luminal-vascular area decreased while the stromal area remained stable, resulting in a decrease in the ratio of vascular area to total area.²⁶

In a study evaluating the choroidal structure in hyperopic amblyopic eyes, CVI was found to be higher in amblyopic eyes compared to fellow eyes and was positively correlated with SFCT.²⁴ In the present study, CVI was significantly lower in eyes with hyperopic anisometropic amblyopia compared to fellow eyes and healthy controls. To our knowledge, there is

no study in the literature specifically comparing strabismic amblyopia groups, and this study is the first to evaluate CVI according to the type of amblyopia. No significant differences in CVI were detected between the strabismic amblyopia group and the subgroups. This suggests that the choroidal thickening associated with hyperopic refractive error may not be due to amblyopia and may be caused by high hyperopia. However, previous studies have shown that in hyperopic patients, choroidal thickness increases and vascular structures enlarge in association with the degree of hyperopia.²⁵ In the present study, the stromal component increased more significantly.

In a study of anisometropic amblyopia patients receiving one-year refractive correction and/or occlusion therapy, it was observed that the choroidal vascular component decreased and the stromal component increased in amblyopic eyes after treatment, while no significant change was detected in non-amblyopic eyes.²⁵ This shows that the choroid plays an important role in the pathophysiology and treatment of the disease, especially in eyes with refractive amblyopia. This is supported by the fact that the morphology of the amblyopic eyes after treatment resembled that of the fellow eyes. In the present study, the fact that the stromal component in relation to the luminal area is significantly different in patients receiving treatment compared to the control group may suggest an effect of treatment on choroidal pathophysiology. We believe that post-treatment follow-up of the same patient group and comparison with initial data would support these findings.

Study Limitations

This case-control study has various limitations. The data were calculated manually based on EDI-OCT images. To prevent potential errors arising due to this, the average of data calculated by two experienced researchers was analyzed. The

	Group 1		Group 2		Control Mean ± SD (range)
	Amblyopic eye mean ± SD (range)	Fellow eye mean ± SD (range)	Amblyopic eye mean ± SD (range)	Fellow eye mean ± SD (range)	
BCVA	0.57±0.16 (0.30-0.80)	0.94±0.08 (0.80-1.00)	0.61±0.17 (0.20-0.80)	0.92±0.10 (0.80-1.00)	1.00±0 (1.00-1.00)
SE	3.07±2.85 (0.50-5.00)	2.61±3.46 (0.75-6.00)	4.88±2.83 (2.00-8.00)	2.99±2.51 (0.25-5.50)	0.25±0.50 (0.25-0.50)
SFCT	341.50±60.4 (277-481)	321.92±68.26 (251-440)	370.06±65.36 (247-462)	330.35±74.0 (194-502)	327.62±40.79 (238-385)
CVI	0.681±0.032 (0.641-0.736)	0.685±0.054 (0.587-0.788)	0.664±0.033 (0.592-0.719)	0.707±0.039 (0.625-0.779)	0.688±0.031 (0.612-0.748)
LA	1.011±0.187 (0.690-1.310)	0.964±0.230 (0.560-1.270)	1.106±0.165 (0.770-1.400)	1.012±0.174 (0.570-1.300)	1.105±0.135 (0.830-1.310)

SD: Standard deviation, BCVA: Best corrected visual acuity, SE: Spherical equivalent, SFCT: Subfoveal choroidal thickness, CVI: Choroidal vascular index, LA: Luminal area

amblyopia patients in the study are those being followed up and treated in the pediatric ophthalmology department of our center. We hope to confirm our data in larger scale studies with a sufficient number of treatment-naive patients. In addition, since AL measurements could not be taken, it was not possible to compare the refraction values obtained after cycloplegic drops and other parameters according to AL. The strabismic amblyopia group in our study was also small compared to the other groups. The majority of patients with strabismic amblyopia also have refractive errors, which limited the number of patients in this group. Although there was no statistically significant difference in the mean, the number of patients in the study groups and their heterogeneity in terms of age distribution constituted a significant limitation of the study. Therefore, studies with larger samples of all groups are needed.

Conclusion

Whether amblyopia is of strabismic or refractive etiology, morphological changes can be seen in the choroid. However, CVI values showed that the stromal component of the choroid was increased in patients with refractive amblyopia.

Ethics

Ethics Committee Approval: Ege University Medical Research Ethics Committee, decision no: 20-4.2T/33, 29.04.2020.

Informed Consent: Approval was obtained from the medical research ethics committee of the university in which the study was conducted, and an informed consent form was signed by the parent or legal guardian of each participant.

Peer-review: Externally peer reviewed.

Authorship Contributions

Surgical and Medical Practices: C.D., O.F., Concept: O.F., E.D.B., F.A., C.A., S.N., Design: O.F., E.D.B., F.A., C.A., S.N., Ö.Ü., Data Collection or Processing: C.D., O.F., Analysis or Interpretation: C.D., O.F., Literature Search: C.D., O.F., Writing: C.D., O.F.

Conflict of Interest: No conflict of interest was declared by the authors.

Financial Disclosure: The authors declared that this study received no financial support.

References

- Taylor V, Bossi M, Greenwood JA, Dahlmann-Noor A. Childhood amblyopia: current management and new trends. *Br Med Bull.* 2016;119:75-86.
- Wallace DK, Repka MX, Lee KA, Melia M, Christiansen SP, Morse CL, Sprunger DT; American Academy of Pediatric Ophthalmology/Strabismus Preferred Practice Pattern Pediatric Ophthalmology Panel. Amblyopia Preferred Practice Pattern®. *Ophthalmology.* 2018;125:105-142.
- Maurer D, McKEE SP. Classification and diversity of amblyopia. *Vis Neurosci.* 2018;35:E012.
- Webber AL. Amblyopia treatment: an evidence-based approach to maximising treatment outcome. *Clin Exp Optom.* 2007;90:250-257.
- von Noorden GK. Amblyopia: a multidisciplinary approach. Proctor lecture. *Invest Ophthalmol Vis Sci.* 1985;26:1704-1716.
- Weinacht S, Kind C, Mönning JS, Gottlob I. Visual development in preterm and full-term infants: a prospective masked study. *Invest Ophthalmol Vis Sci.* 1999;40:346-353.
- Daw NW. Critical periods and amblyopia. *Arch Ophthalmol.* 1998;116:502-505.
- Vagge A, Nelson LB. Amblyopia update: new treatments. *Curr Opin Ophthalmol.* 2016;27:380-386.
- Nickla DL, Wallman J. The multifunctional choroid. *Prog Retin Eye Res.* 2010;29:144-168.
- Chiang ST, Phillips JR, Backhouse S. Effect of retinal image defocus on the thickness of the human choroid. *Ophthalmic Physiol Opt.* 2015;35:405-413.
- Li J, Ji P, Yu M. Meta-analysis of retinal changes in unilateral amblyopia using optical coherence tomography. *Eur J Ophthalmol.* 2015;25:400-409.
- Liu Y, Dong Y, Zhao K. A Meta-Analysis of Choroidal Thickness Changes in Unilateral Amblyopia. *J Ophthalmol.* 2017;2017:2915261.
- Agrawal R, Gupta P, Tan KA, Cheung CM, Wong TY, Cheng CY. Choroidal vascularity index as a measure of vascular status of the choroid: Measurements in healthy eyes from a population-based study. *Sci Rep.* 2016;6:21090.
- Agrawal R, Salman M, Tan KA, Karampelas M, Sim DA, Keane PA, Pavesio C. Choroidal Vascularity Index (CVI) - A Novel Optical Coherence Tomography Parameter for Monitoring Patients with Panuveitis? *PLoS One.* 2016;11:e0146344.
- Ostrin LA, Jnawali A, Carkeet A, Patel NB. Twenty-four hour ocular and systemic diurnal rhythms in children. *Ophthalmic Physiol Opt.* 2019;39:358-369.
- Burfield HJ, Patel NB, Ostrin LA. Ocular Biometric Diurnal Rhythms in Emmetropic and Myopic Adults. *Invest Ophthalmol Vis Sci.* 2018;59:5176-5187.
- Sonoda S, Sakamoto T, Yamashita T, Shirasawa M, Uchino E, Terasaki H, Tomita M. Choroidal structure in normal eyes and after photodynamic therapy determined by binarization of optical coherence tomographic images. *Invest Ophthalmol Vis Sci.* 2014;55:3893-3899.
- Steiner M, Esteban-Ortega MDM, Muñoz-Fernández S. Choroidal and retinal thickness in systemic autoimmune and inflammatory diseases: A review. *Surv Ophthalmol.* 2019;64:757-769.
- Jin P, Zou H, Zhu J, Xu X, Jin J, Chang TC, Lu L, Yuan H, Sun S, Yan B, He J, Wang M, He X. Choroidal and Retinal Thickness in Children With Different Refractive Status Measured by Swept-Source Optical Coherence Tomography. *Am J Ophthalmol.* 2016;168:164-176.
- Araki S, Miki A, Goto K, Yamashita T, Takizawa G, Haruishi K, Ieki Y, Kiryu J, Yaoeda K. Macular retinal and choroidal thickness in unilateral amblyopia using swept-source optical coherence tomography. *BMC Ophthalmol.* 2017;17:167.
- Kara O, Altintas O, Karaman S, Emre E, Çağlar Y. Analysis of Choroidal Thickness Using Spectral-Domain OCT in Children With Unilateral Amblyopia. *J Pediatr Ophthalmol Strabismus.* 2015;52:159-166.
- Celik E, Çakır B, Turkoglu EB, Doğan E, Alagoz G. Evaluation of the retinal ganglion cell and choroidal thickness in young Turkish adults with hyperopic anisometropic amblyopia. *Int Ophthalmol.* 2016;36:515-520.
- Aygit ED, Yılmaz I, Ozkaya A, Alkin Z, Gokyigit B, Yazici AT, Demirok A. Choroidal thickness of children's eyes with anisometropic and strabismic amblyopia. *J AAPOS.* 2015;19:237-241.

24. Baek J, Lee A, Chu M, Kang NY. Analysis of Choroidal Vascularity in Children with Unilateral Hyperopic Amblyopia. *Sci Rep.* 2019;9:12143.
25. Nishi T, Ueda T, Mizusawa Y, Semba K, Shinomiya K, Mitamura Y, Sonoda S, Uchino E, Sakamoto T, Ogata N. Effect of optical correction on choroidal structure in children with anisohypermetropic amblyopia. *PLoS One.* 2020;15:e0231903.
26. Ruiz-Medrano J, Ruiz-Moreno JM, Goud A, Vupparaboina KK, Jana S, Chhablani J. Age-Related Changes In Choroidal Vascular Density Of Healthy Subjects Based On Image Binarization Of Swept-Source Optical Coherence Tomography. *Retina.* 2018;38:508-515.