



Long-term Follow-up Results of Primary Canaliculitis Patients

Emine Gökçen Bayuk*, Emine Malkoç Şen*, Fatma Çorak Eroğlu*, Kübra Serbest Ceylanoğlu*, Ebru Evren**

*University of Health Sciences Türkiye, Ulucanlar Eye Training and Research Hospital, Ankara, Türkiye

**Ankara University Faculty of Medicine, Department of Medical Microbiology, Ankara, Türkiye

Abstract

Objectives: To evaluate the demographic characteristics, clinical presentation, microbiologic profile, and treatment results of patients with primary canaliculitis.

Materials and Methods: Patients diagnosed and treated for primary canaliculitis between May 2014 and May 2021 were analyzed retrospectively.

Results: There were 26 patients with primary canaliculitis, including 17 females (65.4%) and 9 males (34.6%) with a mean age of 50.6±16.4 years (range: 9-80 years). Canaliculitis affected the right eye in 11 patients, the left eye in 13 patients, and bilateral involvement was seen in 2 patients. Inferior canaliculus involvement was more frequent (73%). The most common complaint was epiphora (46.1%). Five patients (19.2%) were wrongly diagnosed as chronic conjunctivitis. The time interval between the beginning of symptoms and canaliculitis diagnosis was 18.2±14.3 months (range: 1-60 months). Canaliculotomy and curettage of canalicular content with dacryolith removal were performed in 23 patients. After surgery, antibiotic irrigation of the canaliculus was added to the treatment regimen in 12 of these 23 patients. Intracanalicular antibiotic therapy was administered to the remaining 3 patients. The most cultured organism was *Actinomyces* (6 patients), *Gemella* (1 patient), *Porphyromonas* (1 patient), *Candida parapsilosis* (1 patient), *Citrobacter koseri* (1 patient) were also grown in culture. The follow-up time of patients was 26.2±23.7 months (range: 6-83 months). All symptoms and findings resolved in all patients in one month. In two patients, recurrence occurred at 4 and 16 months after surgical treatment. With appropriate treatment, no further recurrence was seen in either patient over 24-month follow-up. One patient presented with iatrogenic canaliculus blockage during follow-up.

Conclusion: Primary canaliculitis is often overlooked and can be misdiagnosed. The most common symptom was epiphora. All patients with epiphora and chronic conjunctivitis should be examined carefully for canaliculitis.

Keywords: Actinomyces, canaliculitis, canaliculotomy, conjunctivitis, curettage

Introduction

Primary canaliculitis is chronic inflammation of the proximal lacrimal pathway.¹ The most common signs and symptoms are epiphora, medial canthal swelling, punctal or canalicular edema, pouting punctum, lower eyelid erythema, concretions, and mucopurulent discharge. As the manifestations of canaliculitis are similar to other diseases of the lacrimal apparatus, in many cases the diagnosis is delayed or misdiagnosed as chronic conjunctivitis, chalazion, or dacryocystitis, resulting in inadequate or incorrect treatment.^{2,3} Treatment with topical eye drops alone results in a high recurrence rate.⁴ Surgical removal of concretions is considered imperative for a permanent cure, and the benefits over conservative treatment have been proven.⁵

The specific objective of this study was to evaluate the demographic characteristics, treatments, and long-term outcomes of patients with primary canaliculitis.

Materials and Methods

The medical records of patients diagnosed as having primary canaliculitis in the oculo-plasty unit of our hospital between May 2014 and May 2021 were reviewed retrospectively. Ethics committee approval was obtained from the Ankara Bilkent City Hospital Clinical Research Ethics Committee (date of approval: 17/11/2021; protocol no: E1/2114/2021). The diagnosis of primary canaliculitis was based on clinical symptoms and signs.

Cite this article as: Bayuk EG, Malkoç Şen E, Çorak Eroğlu F, Serbest Ceylanoğlu K, Evren E. Long-Term Follow-up Results of Primary Canaliculitis Patients. Turk J Ophthalmol 2023;53:149-153

Address for Correspondence: Emine Gökçen Bayuk, University of Health Sciences Türkiye, Ulucanlar Eye Training and Research Hospital, Ankara, Türkiye
E-mail: gokcenyuksel1@yahoo.com ORCID-ID: orcid.org/0000-0002-8243-304X
Received: 08.01.2022 Accepted: 11.09.2022

DOI: 10.4274/tjo.galenos.2022.37659

Data including patients' demographic characteristics, symptoms, symptom durations, previous clinical diagnoses, treatments, and long-term outcomes were collected. All patients were diagnosed based on clinical findings such as epiphora, punctal or canalicular edema, erythema ([Figure 1](#)), concretions ([Figure 2](#)), and purulent discharge from the punctum upon gentle pressure. [Figure 2](#) shows one of our patients with sulfur granules.

Inclusion criteria were the presence of clinical findings suggesting typical canaliculitis and patent lacrimal syringing of the unaffected canaliculi. Exclusion criteria were cases of secondary canaliculitis due to foreign body in the punctum and canaliculus (e.g., eyelash, punctal plug) and obstruction of nasolacrimal duct drainage.

We applied two different treatment modalities. Intracanalicular antibiotic therapy was administered to patients who presented early (within 6 months) and had mild symptoms, patent lacrimal syringing through the unaffected canaliculi, dacryoliths, and purulent discharge from the punctum when mild pressure was applied. For patients who presented late (after 6 months; dacryoliths tend to be indurated in the late period), had recurrent canaliculitis, and/or were misdiagnosed underwent canaliculotomy and curettage of canalicular content with dacryolith removal. Depending on clinical severity, some patients received postoperative intracanalicular antibiotic treatment daily for the first week, then weekly for one month ([Figure 3](#)).

In intracanalicular antibiotic therapy without surgery, the canaliculus was irrigated with cefuroxime (750 mg/mL, 6 mL; Deva Holding, İstanbul, Türkiye) once a day for 5 days. A wide spectrum of topical antibiotics was given 8 times a day until the assessment of microbiologic culture results.

In surgical treatment, after local anesthesia, a Bowman lacrimal probe was passed into the affected canaliculus and an incision was made with a number 11 blade in the affected canaliculus. Canalicular curettage was performed using a chalazion curette. The canaliculi were irrigated with cefuroxime (750 mg/mL, 6 mL). The patients were treated with hot compresses and topical fluoroquinolone 8 times daily for 10 days. After canaliculotomy, intracanalicular cefuroxime was applied daily for the first week, then weekly for one month.

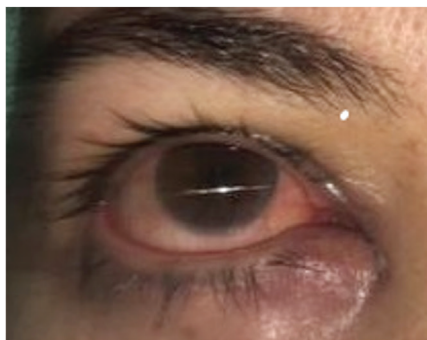

Figure 1. Clinical appearance of the right inferior punctum before treatment in a patient with primary canaliculitis. Hyperemia of the conjunctiva and edematous inferior canaliculus are evident

The antibiotic regimen was refined according to culture results and sensitivities. No silicone intubation or reconstruction was performed.

Dacryoliths and purulent material obtained during surgery were sent to the microbiology laboratory for analysis using anaerobic transport medium. For patients who received only intracanalicular antibiotic therapy, mucopurulent material expressed from the affected canaliculus before antibiotic irrigation was sent to the microbiology laboratory. Direct Gram staining revealed gram-positive, branching filamentous structures. Cultures were performed to ascertain the presence of aerobic and anaerobic bacteria and fungi. Columbia agar was incubated at 37 °C in anaerobic conditions for 5 days. Blood agar and MacConkey agar plates were incubated at 37 °C for 24-48 hours. Sabouraud dextrose agar plates were incubated at both 25 °C and 37 °C.

Results

Of 26 patients who consented to treatment, 17 (65.4%) were female and 9 (34.6%) were male. The mean age was 50.6±16.4 years (range: 9-80 years). Canaliculitis affected the right eye in 11 patients, the left eye in 13 patients, and was bilateral in 2 patients. Inferior canalicular involvement was more frequent (73%). The most common complaint was epiphora (46.1%). Sixteen patients (61.5%) were misdiagnosed as having chronic conjunctivitis and treated previously. Two patients presented for unresolved epiphora after dacryocystorhinostomy. Other causes of hospital admission were purulent discharge, itching, redness, pain, and swelling of the canalicular area. The mean time from symptom onset to canaliculitis diagnosis was 18.2±14.3 months (range: 1-60 months). The demographic characteristics, treatment, and follow-up data of the patients are shown in [Table 1](#).

Canaliculotomy and curettage of canalicular content with dacryolith removal were performed in 23 patients. After surgery, antibiotic irrigation of the canaliculus was added to the treatment

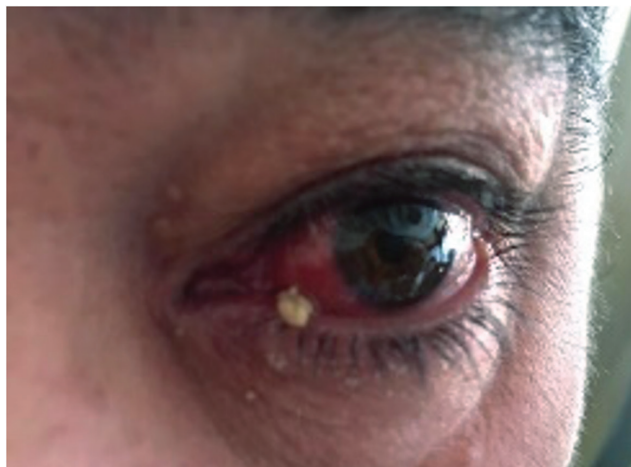


Figure 2. Typical sulfur granule appearance in canaliculitis

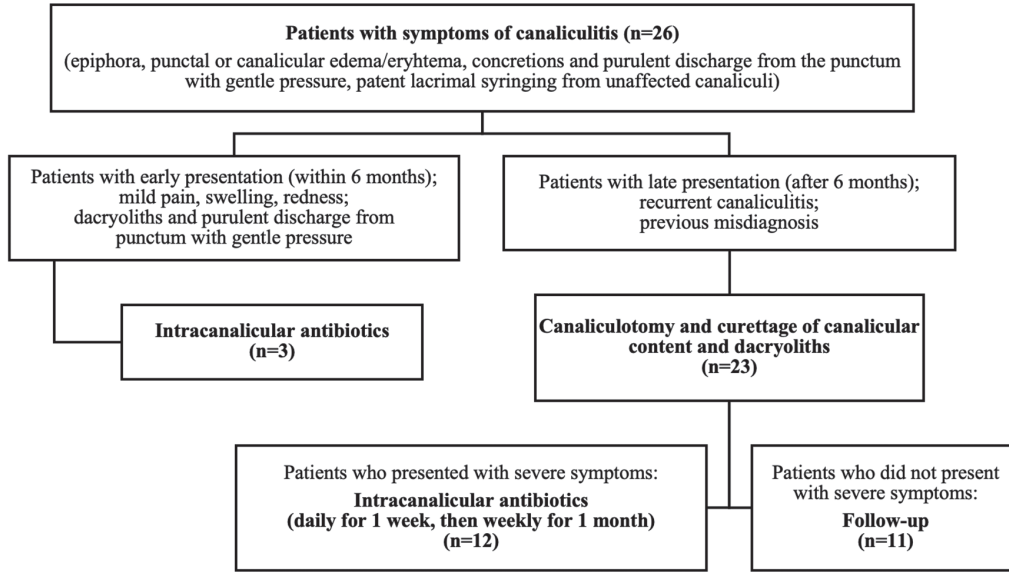


Figure 3. Treatment plan of canaliculitis

regimen in 12 of these 23 patients. The remaining 3 patients who did not undergo surgery received intracanalicular antibiotic therapy. All of these patients had been administered topical treatment with fluoroquinolone.

The most cultured organism was *Actinomyces* (6 patients). *Gemella* (1 patient), *Porphyromonas* (1 patient), *Candida parapsilosis* (1 patient), and *Citrobacter koseri* (1 patient) were also established in culture (Table 2). The mean follow-up time was 26.2±23.7 months (range: 6-83 months). Signs and symptoms resolved in all patients within 1 month. In 2 patients, recurrence occurred at 4 and 16 months after treatment. Canaliculotomy and curettage of canalicular content with dacryolith removal was performed in one of these patients, and intracanalicular antibiotic irrigation was done for the other. After appropriate treatment, no further recurrence was seen in either patient over 24-month follow-up. In 1 patient, iatrogenic canaliculus blockage was diagnosed during follow-up.

Discussion

The canaliculi are an important component of the lacrimal drainage system. They begin at the lacrimal puncta and mostly converge to form the common canaliculus. Canaliculitis is inflammation of the lacrimal canaliculus and accounts for only 2% to 4% of all patients with lacrimal pathology.³ The condition may be misdiagnosed and treated as conjunctivitis, blepharitis, dacryocystitis, or chalazion, thus leading to prolonged morbidity.^{5,6,7} The current study aimed to assess patients with primary canaliculitis and increase awareness of this rare and diagnostically challenging condition.

Canaliculitis is classified as either primary or secondary. While primary canaliculitis is usually caused by an infection, secondary canaliculitis is most commonly associated with punctal

Table 1. Demographic, clinical, and follow-up data of primary canaliculitis patients

	Number (%)
Age (years)*	50.6±16.4 (9-80)
Gender	
Female	17 (65.4)
Male	9 (34.6)
Laterality	
Right	11 (42.3)
Left	13 (50.0)
Bilateral	2 (7.6)
Location	
Superior canaliculus	7 (26.9)
Inferior canaliculus	19 (73.1)
Mean time to diagnosis (months)	18.2±14.3
Follow-up time (months)*	26.2±23.7 (6-83)
Recurrence	2 (7.6)
Iatrogenic canaliculus blockage	1 (3.8)

*Data presented as mean ± standard deviation (range)

Table 2. Microbiological profile of primary canaliculitis patients

Etiologic agent	Number (%)
<i>Actinomyces</i>	6 (23)
<i>Candida parapsilosis</i>	1 (3.8)
<i>Gemella</i>	1 (3.8)
<i>Citrobacter koseri</i>	1 (3.8)
<i>Porphyromonas</i>	1 (3.8)

plug insertion for the treatment of dry eye, intracanalicular plug migration, or a foreign body in the punctum or canaliculus.^{6,8} We only included patients with primary canaliculitis in this study.

Older women have a higher prevalence of canaliculitis in the literature.^{9,10} In our study, females (65.4%) were more affected than males (34.6%) and the patients' mean age was 50.6 ± 16.4 years (range: 9-80 years). Our findings are consistent with the literature.

The masking clinical manifestations of canaliculitis and low awareness among general ophthalmologists often lead to late diagnosis.¹¹ Sixteen of our 26 patients were previously misdiagnosed and treated for chronic conjunctivitis. The mean duration of symptoms prior to canaliculitis diagnosis in our study was 18.2 ± 14.3 months (range: 1-60 months). This is longer than the intervals reported in two other studies by Kaliki et al.¹³ and Kim et al.¹⁴ For this reason, we think that increased awareness is needed to enable early diagnosis, and this condition should be considered when patients present with complaints of epiphora or recurrent conjunctivitis.

Dacryocystography and ultrasound biomicroscopy are widely used for the diagnosis of canaliculitis.⁵ However, the use of a detailed diagnostic tool such as dacryocystography can lead to scar tissue because of iatrogenic trauma and is not absolutely necessary for diagnosis.⁵ In the present study, all patients were diagnosed based on clinical manifestations (epiphora, punctal or canalicular edema, erythema, concretions, and purulent discharge expressed from the punctum with gentle pressure). We did not use dacryocystography or ultrasound biomicroscopy.

Canaliculitis can be misdiagnosed as dacryocystitis or nasolacrimal duct obstruction. Patent irrigation of the nasolacrimal duct through the unaffected canaliculus of the same eye is important in the differential diagnosis.¹⁴

The prevalence of inferior canaliculus involvement was higher (73%) in the present study compared to other studies.^{11,12,15} To our knowledge, there is no explanation in the literature regarding which canaliculi are most affected and the reason for this. Our findings may be related to gravity and the anatomical structure of the inferior canaliculi. The lower canaliculi are almost entirely horizontal and taller than the upper canaliculi,⁶ and gravity may predispose the lower canaliculi to bacterial accumulation. In contrast to our study, Kim et al.¹⁴ reported that the upper and lower canaliculi were equally affected, while Vécsei et al.¹⁶ reported that the upper canaliculus was more frequently involved. Most of the patients in our study had unilateral involvement (92%).

Treatment with only topical antibiotic drops, antibiotic irrigation of the canaliculi, or punctal curettage alone is associated with high recurrence rates. This is because antibiotics are unable to penetrate canalicular concretions.⁵ Kaliki et al.¹³ argued that 41% of patients who were managed without surgery required additional treatment. No additional treatment was needed by our patients treated with intracanalicular antibiotic irrigation. Their symptoms completely resolved. However, these patients needed to come to the hospital more often than patients treated with surgery. Concretions may prevent antibiotics from killing the bacteria and are therefore one of the main risk factors for recurrent canaliculitis.¹⁵

Curettage with or without one-snip punctoplasty and canaliculotomy are the recommended approaches to the surgical treatment of primary canaliculitis.^{2,5,13,16,17,18,19} Canalicular dilation can occur in association with canaliculitis and may lead to canalicular stasis and bacterial propagation.¹⁷ Canalicular dilation was seen in one patient in our study. Yuksel et al.¹⁷ demonstrated that in cases without serious dilation, punctotomy/canaliculotomy and curettage may be sufficient for treatment. Canaliculotomy provides a higher success rate, but scarring and dysfunction of the lacrimal pump may occur. Canaliculoplasty with lacrimal intubation may be essential for a definitive cure in cases with canalicular dilations. This technique prevents iatrogenic canalicular scarring and preserves lacrimal pump function. Canaliculoplasty may have an important role in the prevention of canalicular stasis. Additionally, one-snip punctoplasty was found to be efficacious in cases without significant canalicular dilation.¹⁷

In the literature, there is one study that compared anatomical and functional success rates between patients with and without silicone tube intubation.² Wang et al.² reported that canaliculotomy with silicone tube intubation showed better outcomes, with significantly higher anatomical (100% vs. 73.8%) and functional success rates (87.5% vs. 60.9%) than in the group without silicone tube intubation. However, complete resolution of canalicular edema, erythema, and purulent discharge was seen in all patients postoperatively, and no recurrent infections were observed in any of the patients during follow-up.² Su et al.¹ observed complete resolution in 78.6% of patients after canaliculotomy with stent placement. In contrast, in another study complete resolution was achieved in 97.2% of the patients after canaliculotomy and curettage without stent intubation.¹⁵ In the current study, no stent placement was performed and complete remission was achieved in 92% of the patients with a mean follow-up time of 26.2 ± 23.7 months. Unfortunately, performing canaliculotomy with stent intubation was not an option because of the higher cost of stents in our hospital. Nevertheless, our results clearly demonstrate that canaliculotomy without stent intubation may be a good choice for these patients.

In our study, only one patient had canaliculus obstruction at follow-up, while the other patients had good canalicular function. We achieved a high functional success rate using canaliculotomy and curettage of canalicular content with dacryolith removal.

Canaliculitis severity and symptom duration are important criteria guiding our treatment approach. We applied intracanalicular antibiotics to patients with early presentation (within 6 months) and mild symptoms (3 patients). However, antibiotic irrigation is not appropriate for patients with accumulated stones in the canaliculi and severe symptoms. In these patients, we performed canaliculotomy and curettage of canalicular content with dacryolith removal. This surgical procedure was performed for 23 of our 26 patients. After surgery, antibiotic irrigation of the involved canaliculus was added to the treatment regimen if the patients had severe symptoms, recurrent canaliculitis, and presence of concretions ([Figure 3](#)).

In the literature, success rates in the conservative treatment of primary canaliculitis vary between 0% and 34.7%, while 80-100% recovery is reported after canaliculotomy.^{5,16,18,19} In our study, complete resolution of primary canaliculitis was noted in 100% of our patients in long-term postoperative follow-up. Two patients had recurrence 4 and 16 months after treatment. Canaliculotomy and curettage of canalicular content with dacryolith removal was repeated in one of the patients, and intracanalicular antibiotic irrigation was performed for the other patient. No further recurrence was seen in either patient in 24 months of follow-up.

Conventionally, the causative pathogen of canaliculitis is reported to be *Actinomyces israelii*, an anaerobic gram-positive bacillus. It is associated with chronic purulent granulomatous infection with typical sulfur granules.²⁰ Most recently, studies have shown an increased incidence of *Staphylococcus* and *Streptococcus* species.^{5,9,11,13} Many other uncommon organisms like *Eikenella*, *Lactococcus*, *Nocardia*, and fungi also have been isolated from patients with canaliculitis.⁶ Concretions were initially considered pathognomonic of *Actinomyces*, but many other organisms have also been associated with concretions in other studies.^{11,13,15,21} In the present study, discharge and/or concretions from all patients were sent to the microbiology laboratory for evaluation and microbiological cultures were positive in only 10 patients (38%). *Actinomyces israelii* was most frequently isolated organism in the current study (23%), and other cultured organisms included *Gemella*, *Porphyromonas*, *Candida parapsilosis*, and *Citrobacter koseri*.

This study reflects the long-term results of a tertiary ophthalmology center to which patients were referred from many different centers in our country. However, the main limitation is its retrospective design. Another limitation is that we could not make a comparison between patients who received only intracanalicular antibiotic therapy and those who underwent surgery, because the number of patients who received early treatment was small. However, this led us to believe that diagnosis is usually delayed in these patients, so we need to raise our awareness of early diagnosis.

Conclusion

Canaliculitis is an uncommon lacrimal pathway disease that can be overlooked and misdiagnosed for long periods. As a result, the appropriate treatment is generally delayed. The most common symptom in our patients was epiphora. All patients with epiphora and chronic conjunctivitis should be examined carefully for canaliculitis. The recommended treatment is canaliculotomy and curettage of canalicular content with dacryolith removal. In spite of appropriate treatment, the possibility of recurrence should always be kept in mind.

Ethics

Ethics Committee Approval: Ankara Bilkent City Hospital Clinical Research Ethics Committee (date of approval: 17/11/2021; protocol no: E1/2114/2021).

Peer-review: Externally peer reviewed.

Authorship Contributions

Surgical and Medical Practices: E.M.Ş., F.Ç.E., K.S.C., Concept: E.G.B., E.M.Ş., Design: E.M.Ş., Data Collection or Processing: E.G.B., E.M.Ş., K.S.C., F.Ç.E., E.E., Analysis or Interpretation: E.G.B., E.M.Ş., Literature Search: E.G.B., E.M.Ş., Writing: E.G.B., E.M.Ş., K.S.C., F.Ç.E.

Conflict of Interest: No conflict of interest was declared by the authors.

Financial Disclosure: The authors declared that this study received no financial support.

References

- Su Y, Zhang L, Li L, Fan X, Xiao C. Surgical procedure of canaliculoplasty in the treatment of primary canaliculitis associated with canalicular dilatation. BMC Ophthalmol. 2020;20:245.
- Wang M, Cong R, Yu B. Outcomes of Canaliculotomy with and without Silicone Tube Intubation in Management of Primary Canaliculitis. Curr Eye Res. 2021;46:1812-1815.
- Luo B, Qi X. Utility of 80-MHz Ultrasound Biomicroscopy and Lacrimal Endoscopy in Chronic Lacrimal Canaliculitis. J Ultrasound Med. 2021;40:2513-2520.
- Liyanage SE, Wearne M. Lacrimal canaliculitis as a cause of recurrent conjunctivitis. Optometry. 2009;80:479-480.
- Anand S, Hollingworth K, Kumar V, Sandramouli S. Canaliculitis: the incidence of long-term epiphora following canaliculotomy. Orbit. 2004;23:19-26.
- Feroze KB, Patel BC. Canaliculitis. In: StatPearls. Treasure Island (FL): StatPearls Publishing; 2021.
- Berlin AJ, Rath R, Rich L. Lacrimal system dacryoliths. Ophthalmic Surg. 1980;11:435-436.
- Singh M, Gautam N, Agarwal A, Kaur M. Primary lacrimal canaliculitis - A clinical entity often misdiagnosed. J Curr Ophthalmol. 2018;30:87-90.
- Lin SC, Kao SC, Tsai CC, Cheng CY, Kau HC, Hsu WM, Lee SM. Clinical characteristics and factors associated the outcome of lacrimal canaliculitis. Acta Ophthalmol. 2011;89:759-763.
- Pavilack MA, Frueh BR. Thorough curettage in the treatment of chronic canaliculitis. Arch Ophthalmol. 1992;110:200-202.
- Alam MS, Poonam NS, Mukherjee B. Outcomes of canaliculotomy in recalcitrant canaliculitis. Saudi J Ophthalmol. 2019;33:46-51.
- Kaliki S, Ali MJ, Honavar SG, Chandrasekhar G, Naik MN. Primary canaliculitis: clinical features, microbiological profile, and management outcome. Ophthalmic Plast Reconstr Surg. 2012;28:355-360.
- Kim UR, Wadwekar B, Prajna L. Primary canaliculitis: The incidence, clinical features, outcome and long-term epiphora after snip-punctoplasty and curettage. Saudi J Ophthalmol. 2015;31:274-277.
- Balıkoğlu Yılmaz M, Şen E, Evren E, Elgin U, Yılmazbaş P. Canaliculitis Awareness. Turk J Ophthalmol. 2016;46:25-29.
- Xiang S, Lin B, Pan Q, Zheng M, Qin X, Wang Y, Zhang Z. Clinical features and surgical outcomes of primary canaliculitis with concretions. Medicine (Baltimore). 2017;96:e6188.
- Vécsei VP, Huber-Spitzy V, Arockar-Mettinger E, Steinkogler FJ. Canaliculitis: difficulties in diagnosis, differential diagnosis and comparison between conservative and surgical treatment. Ophthalmologica. 1994;208:314-317.
- Yuksel D, Hazirolan D, Sungur G, Duman S. Actinomyces canaliculitis and its surgical treatment. Int Ophthalmol. 2012;32:183-186.
- Briscoe D, Edelstein E, Zacharopoulos I, Keness Y, Kilman A, Zur F, Assia EI. Actinomyces canaliculitis: diagnosis of a masquerading disease. Graefes Arch Clin Exp Ophthalmol. 2004;42:682-686.
- Demant E, Hurwitz JJ. Canaliculitis: review of 12 cases. Can J Ophthalmol. 1980;15:73-75.
- Smego RA, Foglia G. Actinomycosis. Clin Infect Dis. 1998;26:1255-1263.
- Joshua R, Matthew S, Adam J. Primary and secondary lacrimal canaliculitis: a review of literature. Surv Ophthalmol. 2011;56:336-347.