



Double Flip Technique for Graft Transfer in Autograft Pterygium Surgery

© Emrah Öztürk, © Abuzer Gündüz

Malatya Turgut Özal University Faculty of Medicine, Department of Ophthalmology, Malatya, Türkiye

Abstract

A 50-year-old man with recurrent pterygium and a 46-year-old woman with primary pterygium underwent surgery using a novel autograft transfer technique that facilitates autograft suturing and ensures correct graft orientation. After removing the pterygium, three edges of the autograft were cut. The autograft was flipped first over the uncut edge and secured to the superior margin of the recipient bed with two sutures. Afterward, the fourth side of the graft was cut and the second flip was done over the sutured edge. Thus, the autograft was in correct surface and side orientation and was sutured to the recipient bed. This simple technique provides both easy transfer and correct orientation of the graft in autograft pterygium surgery.

Keywords: Double flip technique, conjunctiva, cornea, autograft, pterygium

Address for Correspondence: Emrah Öztürk, Malatya Turgut Özal University Faculty of Medicine, Department of Ophthalmology, Malatya, Türkiye
E-mail: marmaraemrah@hotmail.com **ORCID-ID:** orcid.org/0000-0002-3590-3213

Received: 02.06.2022 **Accepted:** 30.09.2022

Cite this article as: Öztürk E, Gündüz A. Double Flip Technique for Graft Transfer in Autograft Pterygium Surgery.
Turk J Ophthalmol 2023;53:58-66

©Copyright 2023 by Turkish Ophthalmological Association
Turkish Journal of Ophthalmology, published by Galenos Publishing House.

Introduction

Pterygium is a wing-shaped fibrovascular conjunctival extension onto the cornea.¹ As pterygium is a common disorder, pterygium surgery is one of the most frequently performed eye surgeries.² Ideally, pterygium surgery should prevent recurrence, because postoperative recurrence is an annoying problem for both patients and surgeons.³ Currently, the preferred method of pterygium surgery is conjunctival autografting because of its lower recurrence rates after pterygium removal.^{1,4} However, several complications such as graft edema, corneoscleral dellen, conjunctival inclusion cyst, and graft necrosis are observed in conjunctival autografting.^{5,6} Conjunctival autografting also involves challenges such as suturing difficulties due to shrinkage and inverse implantation of the graft.⁵ When all edges of a conjunctival autograft are cut, graft orientation can easily be lost during transfer and after suture or sponge contact.⁶ Free conjunctival graft inversion may reduce surgical success by causing graft necrosis. It has also been reported that limbal-fornix disorientation of the graft may cause conjunctival graft edema.⁵

In our patients, we developed a novel graft transfer technique that facilitates graft suturing and ensures proper limbal-fornix and epithelial side up orientation.

Case Report

The first patient is a 50-year-old man who underwent pterygium excision and primary closure 5 years ago. Pterygium recurred 1 year after surgery, and the recurrent pterygium tissue extended approximately 3 mm onto the cornea. In the second case, a 46-year-old woman had a primary pterygium extending approximately 2 mm onto the cornea. Using a novel autograft transfer technique, both cases underwent pterygium excision with limbal conjunctival autograft transplantation (LCAT) (Figure 1). No recurrence was observed in either patient at 6 months postoperatively.

Surgical Technique

Topical 0.5% proparacaine hydrochloride (Alcaine, Alcon, Switzerland) followed by 5% povidone-iodine solution is used for ocular surface sterilization. After cleaning the eyelashes and eyelids with 5% povidone-iodine solution, a surgical drape is placed and an ocular speculum is introduced. Subconjunctival anesthesia is administered to the area with pterygium and the superotemporal bulbar conjunctiva with a 27-gauge needle (1 mL 20 mg lidocaine HCl and 0.0125 mg epinephrine; Jetokain, Adeka AS, Samsun, Türkiye). The stages of the double flip technique are demonstrated in Figure 2. The cap and head of

the pterygium are separated and removed from the corneal surface by blunt dissection using a spatula. The corneal surface is polished after removing the residual tags of pterygium tissue. The pterygium tissue is excised with Westcott scissors. Minimal cauterization is used to control bleeding.

The size of the limbal defect is measured using a Castroviejo caliper, and the caliper tips are marked with a surgical marker pen. The autograft site is determined by making two flips of the marked caliper in the superotemporal direction. Scissors are used to cut the vertical edge of the autograft farthest from the recipient bed, followed by the superior edge close to the fornix. The conjunctival autograft is dissected carefully to avoid damaging Tenon's tissue. Afterward, the limbal edge is cut, and the autograft tissue is flipped over the uncut edge (closest to the recipient bed). While preparing the autograft, attention is paid to ensure that it is wider on the fornix side, in proportion to the recipient bed, and will cover an additional 1 mm of attached superficial limbal epithelium.

After the first flip, the free vertical edge of the autograft is sutured to the conjunctival margin at the superior edge of the recipient bed with two interrupted 8-0 vicryl (Johnson & Johnson, Livingston, UK) sutures. Making these two sutures perpendicular to the edges, slightly away from the corners, and not too tight facilitates the second flip of the autograft and prevents the autograft from shrinking and shortening. Afterward, the fourth side is cut, and the autograft is flipped a second time over the sutured edge and positioned on the recipient bed. First the corners and then the edges of the autograft are secured to the adjacent conjunctiva and episclera with interrupted 8-0 Vicryl sutures.

With this double flip technique, the autograft is transferred to the recipient bed in proper limbal-fornix and epithelial side up orientation (Figure 2H). Following removal of the ocular speculum, antibiotic eye ointment is applied and the eye is covered with an eye patch.

Discussion

Numerous methods have been used for the treatment of pterygium and the prevention of pterygium recurrence. The bare sclera technique allows re-epithelialization of the scleral bed after simple excision of the pterygium. This approach is appealing due to its short surgical time and easy application, but it is rarely used today due to the high risk of recurrence (24-89%).⁷ Conjunctival autografting involves covering the exposed scleral bed after pterygium excision with a free autograft from the

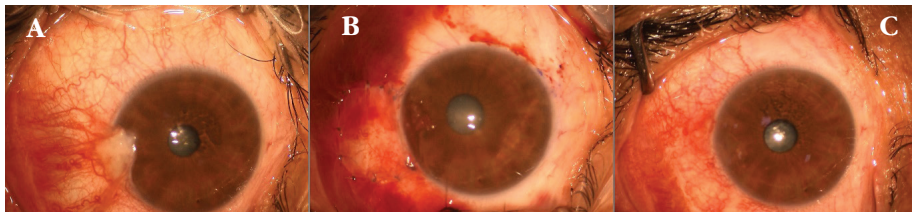

Figure 1. The second patient operated using the double flip technique. A) Preoperative appearance of pterygium. B) Early postoperative appearance of the autograft. C) Postoperative 1-month appearance of the autograft

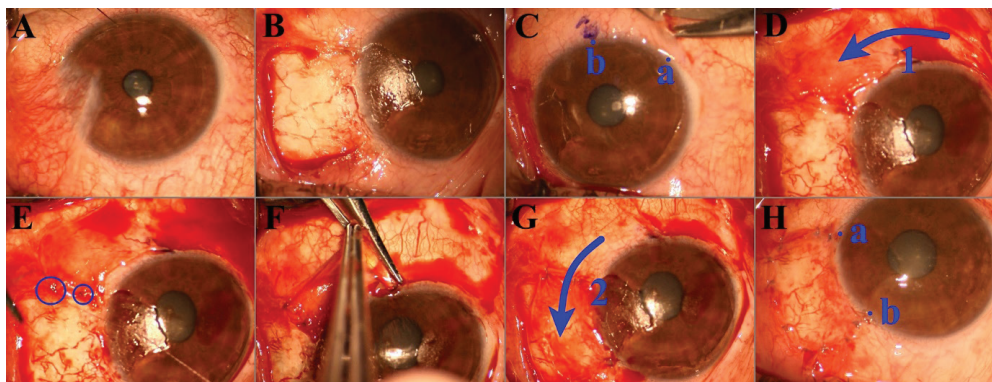


Figure 2. Stages of the double flip technique in the first patient. A) Preoperative appearance of the pterygium. B) Recipient bed prepared after pterygium excision. C) Marking the length of the limbal edge of the autograft. D) First flip of the autograft over the uncut nasal edge after cutting the first three sides. E) First two sutures anchoring the free vertical edge of the autograft to the superior conjunctival margin of the recipient bed. F) Cutting the nasal side of the autograft with Westcott scissors. G) Second flip of the autograft with preserved a-b orientation, sutured to the recipient bed

conjunctiva. Conjunctival autografting is widely used because it effectively prevents pterygium recurrence, but it requires technical expertise and a prolonged operative time.⁸ Furthermore, amniotic membrane is used to cover the exposed scleral bed after pterygium excision. Studies show that while amniotic membrane is associated with less recurrence compared to the bare sclera technique, the recurrence rate is higher than with conjunctival autograft.^{9,10}

Pterygium is believed to occur due to a local limbal deficiency, probably caused by chronic ultraviolet-related damage to limbal stem cells.¹¹ Healthy limbal tissue serves as a barrier that inhibits subconjunctival tissue invasion onto the cornea. LCAT is used in pterygium surgery to reduce pterygium recurrence by restoring limbal function.⁴ In a meta-analysis, LCAT was found to have a lower recurrence rate (0-17%) than all other surgical techniques and practices, including bulbar conjunctival autograft.¹² This result also supports the importance of limbal cells. Therefore, it is crucial to keep the correct (limbal and surface epithelial) directional and surface orientation of the graft while moving it to the recipient bed to increase surgical success and reduce complications.¹³

Various methods are described to prevent graft inversion and limbal-fornix disorientation: marking or cauterizing the graft edge, marking the graft with the letter “G”, and the fibrin glue method.^{6,13} In these methods, a free graft is obtained by cutting all four sides of the graft. Other than with the “G” marking technique, limbal or surface disorientation of the autograft may occur while transferring and suturing the free graft. Our technique ensures proper limbal-fornix and epithelial side up orientation of the graft onto the recipient bed. Unlike the methods described above, it provides easier transfer and suturing because at least one graft edge is always fixed (which is superior to the “G” marking technique). Other advantages of our technique are that the first two sutures become embedded after the second flip and can be easily used in different graft fixation methods (e.g., suturing, fibrin glue, autologous fibrin in blood, electrocautery pen).

The double flip technique may reduce complications and increase surgical success as it ensures both easy transfer and correct orientation of the graft.

Ethics

Informed Consent: Obtained.

Peer-review: Externally peer reviewed.

Authorship Contributions

Surgical and Medical Practices: E.Ö., Concept: A.G., Design: E.Ö., Data Collection or Processing: E.Ö., Analysis or Interpretation: A.G., Literature Search: E.Ö., A.G., Writing: E.Ö., A.G.

Conflict of Interest: No conflict of interest was declared by the authors.

Financial Disclosure: The authors declared that this study received no financial support.

References

- Fonseca EC, Rocha EM, Arruda GV. Comparison among adjuvant treatments for primary pterygium: a network meta-analysis. *Br J Ophthalmol.* 2018;102:748-756.
- Liu L, Wu J, Geng J, Yuan Z, Huang D. Geographical prevalence and risk factors for pterygium: a systematic review and meta-analysis. *BMJ Open.* 2013;3:e003787. Erratum in: *BMJ Open.* 2017;7:e003787corr1.
- Ozdamar Y, Mutevelli S, Han U, Ileri D, Onal B, Ilhan O, Karakaya J, Zilelioglu O. A comparative study of tissue glue and vicryl suture for closing limbal-conjunctival autografts and histologic evaluation after pterygium excision. *Cornea.* 2008;27:552-558.
- Chu WK, Choi HL, Bhat AK, Jhanji V. Pterygium: new insights. *Eye (Lond).* 2020;34:1047-1050.
- Starck T, Kenyon KR, Serrano F. Conjunctival autograft for primary and recurrent pterygia: surgical technique and problem management. *Cornea.* 1991;10:196-202.
- Goktas S, Sakarya Y, Ozcimen M, Sakarya R. Discrimination of Epithelial Face of Conjunctival Autograft in Pterygium Surgery with Fibrin Glue. *Eye Contact Lens.* 2015;41:e18-e19.
- Kaufman SC, Jacobs DS, Lee WB, Deng SX, Rosenblatt MI, Shtein RM. Options and adjuvants in surgery for pterygium: a report by the American Academy of Ophthalmology. *Ophthalmology.* 2013;120:201-208.
- Nuzzi R, Tridico F. How to minimize pterygium recurrence rates: clinical perspectives. *Clin Ophthalmol.* 2018;12:2347-2362.
- Tananuvat N, Martin T. The results of amniotic membrane transplantation for primary pterygium compared with conjunctival autograft. *Cornea.* 2004;23:458-463.
- Ozer A, Yildirim N, Erol N, Yurdakul S. Long-term results of bare sclera, limbal-conjunctival autograft and amniotic membrane graft techniques in primary pterygium excisions. *Ophthalmologica.* 2009;223:269-273.
- Tseng SC. Concept and application of limbal stem cells. *Eye (Lond).* 1989;3:141-157.
- Zheng K, Cai J, Jhanji V, Chen H. Comparison of pterygium recurrence rates after limbal conjunctival autograft transplantation and other techniques: meta-analysis. *Cornea.* 2012;31:1422-1427.
- Figueira EC, Coroneo MT, Francis IC. Preventing conjunctival autograft inversion in pterygium surgery. *Br J Ophthalmol.* 2007;91:83-84.