



Evaluation of the Long-Term Clinical Results of 3 Patients Implanted with the Argus II Retinal Prosthesis

© Dilek Güven*, © Eyüp Düzgün**, © Oğuz Kaan Kutucu***, © Cengiz Gül***

*Acıbadem Maslak Hospital, Clinic of Ophthalmology, İstanbul, Türkiye

**University of Health Sciences Türkiye Sultan 2. Abdulhamid Han Training and Research Hospital, Clinic of Ophthalmology, İstanbul, Türkiye

***University of Health Sciences Türkiye Şişli Hamidiye Etfal Training and Research Hospital, Clinic of Ophthalmology, İstanbul, Türkiye

Abstract

This study presents the long-term clinical results of Argus II retinal prosthesis implantation in eyes with light perception and projection in 3 patients with end-stage retinitis pigmentosa. No conjunctival erosion, hypotony, or implant displacement was observed during postoperative follow-up. The electrical threshold values were lower in the macular region and higher close to the tack fixation region and peripherally. Optical coherence tomography scans showed fibrosis and retinoschisis formation at the retina-implant interface in two cases. This was attributed to mechanical and electrical effects on the tissue due to the active daily use of the system and the electrodes' proximity to the retina. The patients were able to integrate the system into their daily lives and perform activities that they could not do before. Studies on retinal prostheses for the rehabilitation of hereditary retinal diseases are ongoing, so both social and clinical observations and experiences related to the implant are valuable.

Keywords: Retinitis pigmentosa, retinal prosthesis, Argus II implant, optical coherence tomography

Address for Correspondence: Eyüp Düzgün, University of Health Sciences Türkiye, Sultan 2. Abdulhamid Han Training and Research Hospital, Clinic of Ophthalmology, İstanbul, Türkiye

E-mail: r-duzgun@hotmail.com **ORCID-ID:** orcid.org/0000-0003-3803-177X

Received: 04.04.2022 **Accepted:** 23.09.2022

Cite this article as: Güven D, Düzgün E, Kutucu OK, Gül C. Evaluation of the Long-Term Clinical Results of 3 Patients Implanted with the Argus II Retinal Prosthesis System. Turk J Ophthalmol 2023;53:58-66

©Copyright 2023 by Turkish Ophthalmological Association
Turkish Journal of Ophthalmology, published by Galenos Publishing House.

Introduction

Current approaches to human retinal implants are classified as epiretinal, subretinal, suprachoroidal, and scleral (transscleral suprachoroidal).¹ The Argus II Retinal Prosthesis System (Second Sight Medical Products, Inc., Sylmar, CA, USA) is an epiretinal prosthesis that is surgically implanted to provide artificial vision to patients with degenerative diseases of the outer retina.^{2,3} It consists of external and internal components. The internal electrode array, which consists of 60 microelectrodes 200 μm in diameter arranged in a 6x10 grid, is 9x5.5 mm in size, provides 20° of visual field, and is attached to the retina using a retinal tack. The Argus II implant has both a CE mark and FDA approval, and was implanted in more than 350 patients in numerous countries worldwide (information provided by Second Sight).³ In May 2019, Second Sight Medical Products stopped producing the Argus II Retinal Prosthesis. Thus, no new implantations are being performed, but follow-up of implanted patients and necessary updates continue. In this study, we discuss our experiences before, during, and after implantation in a single center in our country.

Case Report

In 2014, the Ophthalmology Clinic of University of Health Sciences Türkiye, Şişli Hamidiye Etfal Training and Research Hospital became the first center in Türkiye to receive certification from Second Sight Medical Products for the implantation of the Argus II Retinal Prosthesis System. More than 500 patients with retinitis pigmentosa (RP) were evaluated in our hospital for eligibility to undergo implantation.⁴ Three patients with end-stage RP who met the eligibility criteria received an Argus II Retinal Prosthesis (phase 1 clinical trial no: NCT00407602). Before the implantation, patients and their relatives were informed about the surgery, device features and operation, associated risks, and realistic expectations, and written informed consent forms were obtained from the patients and their relatives.

Preoperatively, a detailed anterior and posterior segment examination, swinging flashlight test after dark adaptation, and visual acuity examination were performed. Postoperative examinations included anterior and posterior segment photography, fluorescein angiography when necessary, spectral domain optical coherence tomography (OCT) (3D OCT Topcon 2000 FA Tokyo, Japan) with MM6 scanning program and 9-mm section scans, and OCT angiography (OCTA) (AngioVue Avanti RTVue-XR 2017 version; OptoVue, Fremont, CA, USA) with the 12-mm high-density line scan. In the first case, imaging and evaluation could be performed with a prototype OCTA device,⁵ but the results were not evaluated in this study because OCTA scans of sufficient quality could not be obtained with the later version.

Implantation of the Argus II epiretinal prosthesis and the pre- and postoperative medical treatment were carried out as previously described in the literature.⁶ Approximately 10-14 days after surgery, a "fitting" procedure was performed to determine the electrical excitation threshold values of each electrode.⁷ This

procedure was repeated only once, at postoperative 1 month. However, in case 1, the fitting procedure was repeated at 1 year because of the patient's recurrent subjective complaints of low signal reception. Perceptual threshold values were classified as low (1-233 μA), moderate (234-452 μA), high (453-677 μA), and no perception.

At postoperative 1 month, the patients began rehabilitation sessions with an occupational therapist to learn how to use the device and allow them to integrate it into their daily life. Patients received occupational therapy every 2 weeks for 3 months starting from the first month, followed by ophthalmologic examinations every 3 months thereafter until 1 year. In the following period, sessions continued until final follow-up at varying intervals based on the availability of the patient and their relatives.

At the time of writing, the time elapsed since implantation of the Argus II epiretinal prosthesis was 73 months for patient 1, 62 months for patient 2, and 50 months for patient 3. In this study, we discuss the patients' initial findings, early post-implantation findings, and findings at last follow-up at post-implantation 70, 37, and 25 months, respectively, as well as the stimulus threshold values determined in the fitting procedure.

Patient 1 was a 58-year-old man with end-stage RP whose vision in both eyes had decreased over the last 5 years to the level of light perception and projection (LPP). Phacoemulsification, intraocular lens implantation (phaco-IOL), pars plana vitrectomy (PPV), and Argus II implantation were performed in his right eye in January 2016. Preoperatively he had bilateral nuclear sclerosis, intraocular pressure (IOP) was 18 mmHg, and axial length (AL) was 23.13 mm. His last follow-up was performed at 70 months postoperatively. Patient 2 was a 36-year-old man with end-stage RP whose vision in both eyes had also decreased over the last 5 years to the level of LPP. He underwent PPV and Argus II implantation in his right eye in December 2016. Preoperatively, he was pseudophakic bilaterally, his IOP was 12 mmHg, and AL was 24.95 mm. His last follow-up was performed at 37 months postoperatively. Patient 3 was a 43-year-old woman with end-stage RP whose vision had decreased to LPP in both eyes over the last 7 years. She underwent phaco-IOL, PPV, and Argus II implantation in the left eye in December 2017. Preoperatively she had minimal posterior subcapsular opacity bilaterally, IOP was 12 mmHg, and AL was 25.17 mm. Her last follow-up was performed at 25 months postoperatively.

No extraocular adverse events occurred during any of the implantation surgeries. In all patients, all electrodes were active in the electrical stimulation tests performed before, during, and at the end of surgery. None of the patients developed conjunctival surface erosion or hypotony during postoperative follow-up (Figure 1). Topical artificial tears were given for subjective complaints. Eye movements were unrestricted in all directions, and there were no complaints of foreign body sensation. Patient 2 exhibited transient focal dellen due to conjunctival edema in the early postoperative period, which resolved with topical artificial tears. In all patients, fundus examination showed that the electrode array remained in stable contact with the macular region where it was placed, with no rotation (Figure 2A-C).

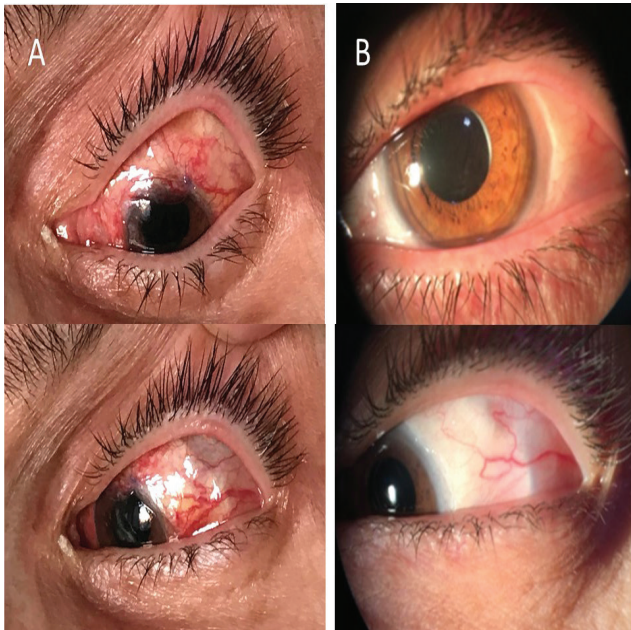

Figure 1. Patient 3: At 1 day after Argus II epiretinal prosthesis implantation, the conjunctiva is hyperemic and sutures are intact (A). Anterior segment images 2 years later show the conjunctiva is intact and the edge of the electronic box is visible under the conjunctiva (B)

When OCT sections were evaluated, the implants remained stable in the early postoperative period and during follow-up in all patients. The formation of a local shallow elevation, referred to as a “snow bank,” was observed at the contact junction between the retina and implant margin. This contact was only at the tack site and the opposing short edge in patient 3. In patient 1, thickening of the retina surrounding the atrophic foveal area and in contact with the implant’s electrode array, enlargement of the contact area, and intraretinal cyst were observed starting at month 6 and becoming pronounced at month 9. In addition, epiretinal membrane extensions were observed around the implant, presumably due to incomplete removal of residual hyaloid. This situation remained stable at the last follow-up at 6 years (Figure 3). In patient 2, thickening of the retina at sites of direct contact with the implant electrode array, dissociation of the retinal layers similar to retinoschisis, and a hyperreflective layer consistent with fibrosis at the interface were observed starting at month 6 and becoming pronounced at month 9, and the area of implant-retina contact enlarged with the increase in retinal thickness (Figure 4). Fundus fluorescein angiography was performed to rule out choroidal neovascularization after observing clinically increased pigmentation inferior to the implant center and thickening of the retinal pigment epithelial layer in OCT sections. In the early phase, pigmentary blockage and hyperfluorescent dots that developed over time were observed, with no increase noted. In the late phase, fading of the fluorescence and mild staining in the area of blockage were observed. This was believed to be attributable to intraretinal cystic spaces, not choroidal neovascularization. It was monitored with palliative topical non-steroidal anti-inflammatory therapy (Figure 5). In these two patients, the retinal thickening

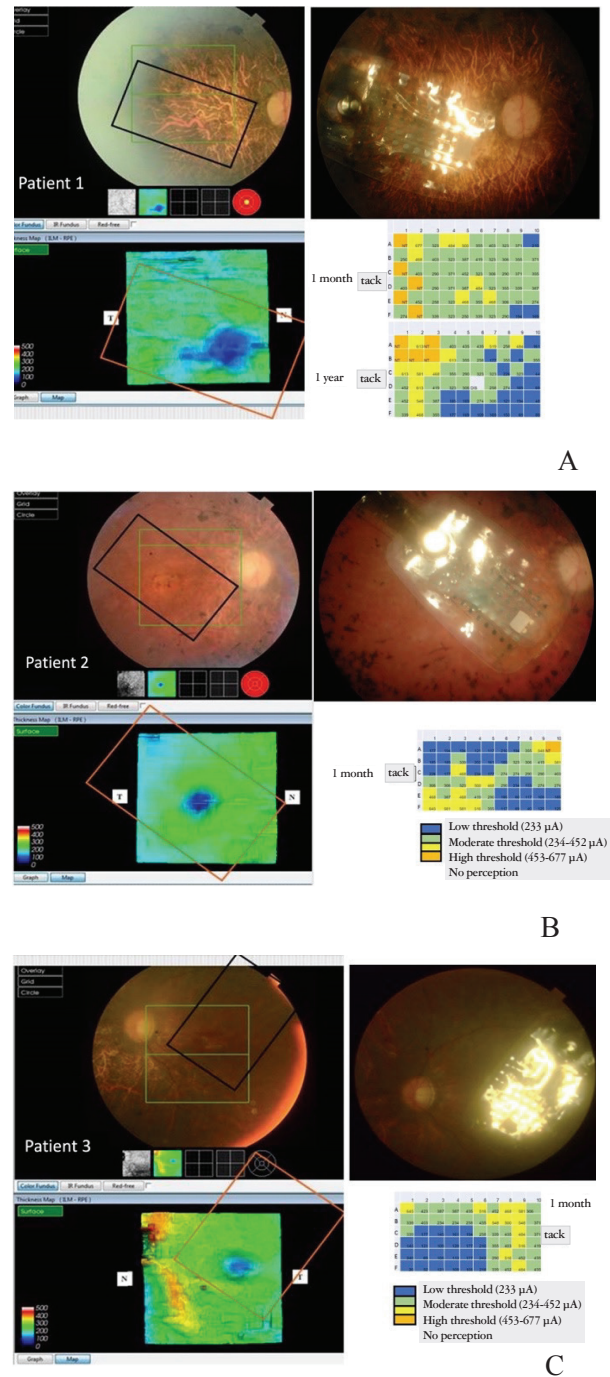


Figure 2. Pre- and post- implantation color fundus photographs and optical coherence tomography retinal thickness maps with markings representing the implant location. Diagrams of electrical stimulation thresholds of the 60 electrodes determined after the fitting procedure performed 1 month and 1 year after implantation in patient 1 (A) and at 1 month after implantation in patients 2 and 3 (B, C)

and edematous appearance after 9 months were considered to be related to the electrical stimulation associated with longer daily duration of active use (2.5-10 hours/day) or a reaction to mechanical contact. In patient 3, the area of direct retina-implant

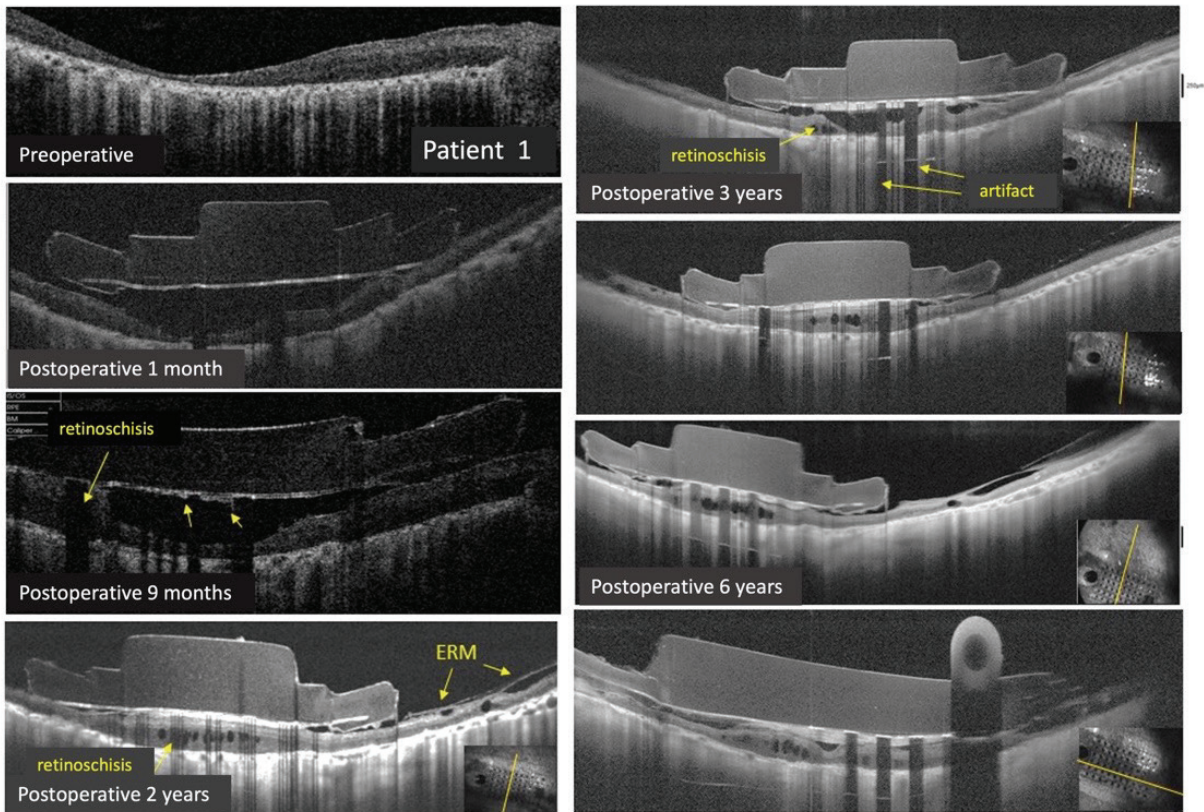


Figure 3. Optical coherence tomography sections obtained in patient 1 at post-implantation 1 month, 9 months, 2 years, 3 years, and last follow-up demonstrate the formation of small intraretinal cysts and fine fibrils on the retina at 9 months, followed by retinal thickening and marked retinoschisis formation at the retina-implant interface and epiretinal membrane (ERM) formation around the implant at 1 year. These features persisted at final follow-up at 6 years

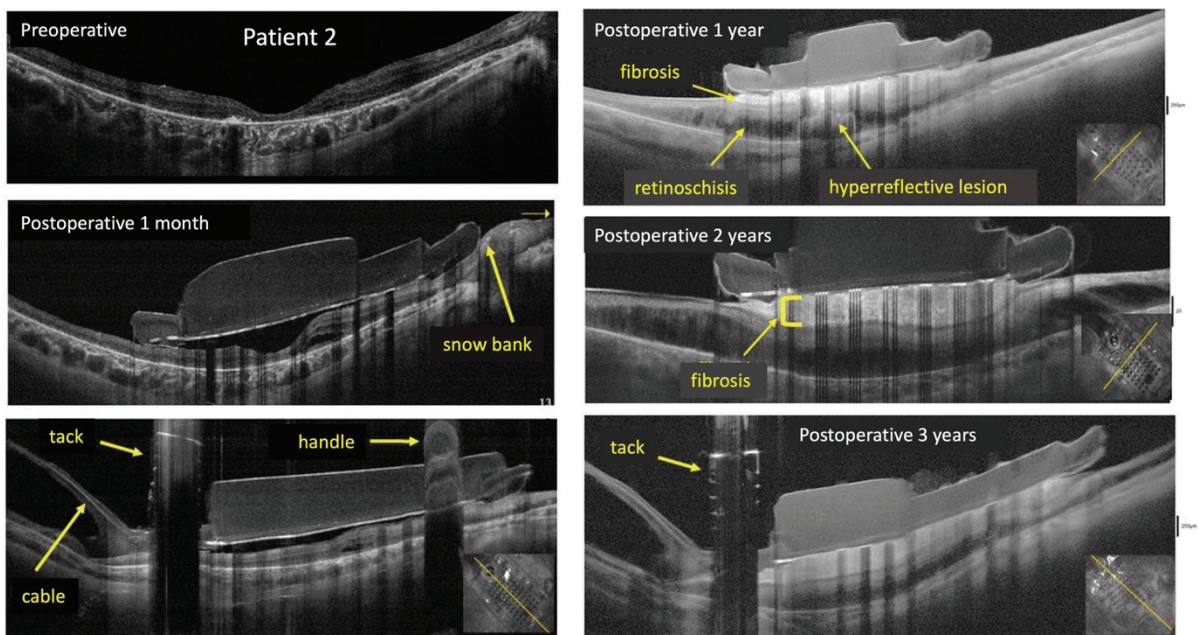


Figure 4. Optical coherence tomography sections obtained in patient 1 at post-implantation 1 month, 1 year, and 3 years show retina thickening along the entire retina-implant interface, the formation of a hyperreflective layer consistent with fibrosis between the implant and retina, and retinoschisis formation at 6 months that was not present at 1 month

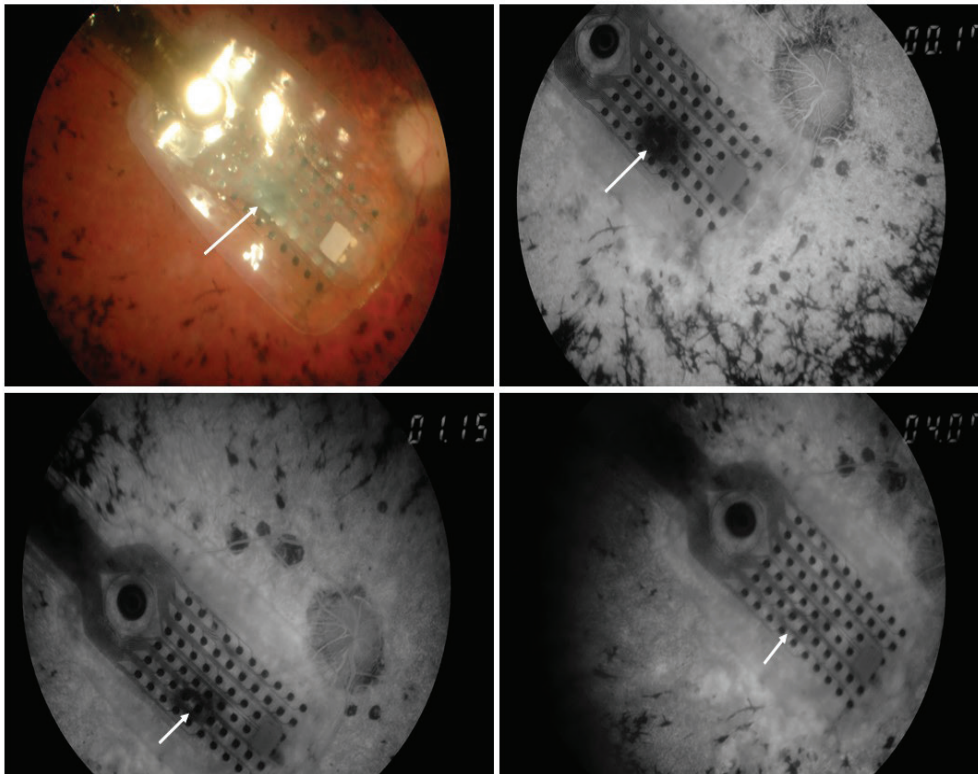


Figure 5. Fluorescein angiography images of patient 2 obtained 1 year after implantation shows focal punctate staining under the implant demonstrating pigmentation-related blockage in the early phase with diffusion and fading of the focal staining in the late phase (arrows)

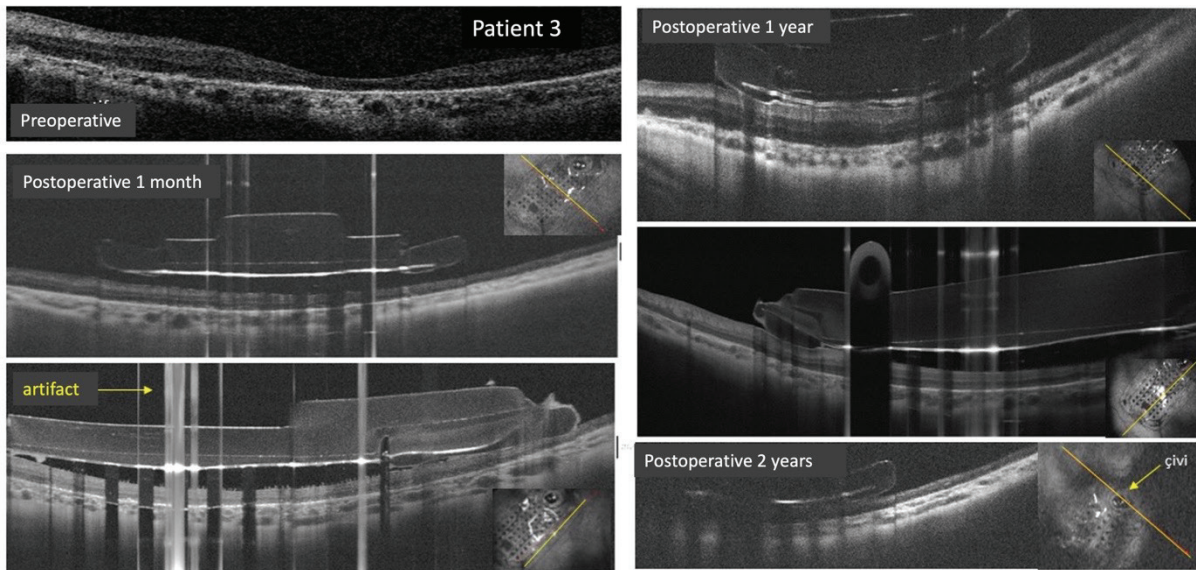


Figure 6. Optical coherence tomography sections obtained in patient 3 at post-implantation 1 month, 1 year, and last follow-up showed that the implant was located close to the retinal surface with no signs of retinal edema or epiretinal membrane

contact was more limited at implant placement and did not correspond to the electrode array, and the daily duration of device usage was shorter than in the other patients (1-2 hours/day). No retinal thickening or development of epiretinal membrane,

fibrotic tissue, or retinoschisis was detected in this patient during follow-up (Figure 6). Although the electrodes, wires, retinal tack, and handle of the implant caused intermittent shadowing artifacts, OCT was found to be generally very effective in

Table 1. Characteristics of patients who received the Argus II epiretinal prosthesis implant

Patient	Age	Gender	Follow-up time	Preop visual acuity	Postop visual acuity	Preop macular status	Postop macular status
1	58	M	70 months	LP + P	LP + P	Atrophic	Signs of retinoschisis and thickening under the implant, thin ERM formation around the implant
2	36	M	37 months	LP + P	LP + P	Atrophic	Signs of retinoschisis under the implant, marked thickening, marked fibrosis
3	43	F	25 months	LP + P	LP + P	Atrophic	No ERM, edema, retinoschisis, or fibrosis was observed.

Preop: Preoperative, Postop: Postoperative, M: Male, F: Female, LP + P: Light perception and projection, ERM: Epiretinal membrane

evaluating the implant site, the relationship between retina and implant, and the findings around the implant (Table 1).

Perceptual threshold values were 89-613 μA in patient 1, 40-645 μA in patient 2, and 20-645 μA in patient 3 (Figure 2A-C). Distributions of perceptual threshold levels at 1 month as a proportion of electrodes were as follows: for patient 1, low in 3/60, moderate in 45/60, high in 7/60, and no phosphene perception in 5/60; for patient 2, low in 28/60, moderate in 19/60, high in 11/60, and no phosphene perception in 1/60; for patient 3, low in 22/60, moderate in 27/60, and high in 11/60. The number of low thresholds was higher in the younger patients. In patient 1, the distribution of threshold values at 1 year was low in 19/60, moderate in 25/60, high in 10/60, no stimulus in 1/60, and no phosphene perception in 5/60. It was observed that the high current values and the electrodes without phosphene perception were in the region around the tack, while the current threshold values decreased in the macular region. Increased threshold values in a larger area in the tack region were found to be associated with possible fibrosis around the tack and a more atrophic retina in the periphery, while decreased threshold values in the macular region were associated with thickening of the retina due to the retinoschisis-like reaction and the proximity of the internal retinal folds to the electrodes in the macular region. In patient 2, the threshold values were found to be high in the region close to the tack and in the electrodes near the optic disc, and one electrode did not elicit phosphene perception at the highest safe threshold value. In patient 3, threshold values were low in the macular region and higher in the tack region, and all electrodes were actively receptive to stimulation. When the patients were evaluated in general, electrical threshold values near the tack (corresponding to the upper temporal macula) and in the periphery were higher, while those in the macular region were lower.

With electrical stimulation, our patients described bright dots. The patients performed exercises such as pointing at a high-contrast (black on white or white on black) 7.3-cm square or determining the direction of 3.7-cm thick bars moving vertically, horizontally, or diagonally across the screen over 2,000 ms on a computer screen at a distance of 30 cm, as well as locating and touching high-contrast objects (Figure 7). In

the next stage, the patients started to use the device at home, at work, or outside, and they were also encouraged to use white canes. The system was actively used on a regular basis for 2.5-10 hours a day for the first 2 years. Patient 1 used the system longer and more effectively, and the outer cable was replaced because the connection site was worn from use. During the coronavirus disease-2019 (COVID-19) pandemic, the patient reported that they had the same cable problem and could not use the system actively during this period because they were unable to present for follow-up. Patients 2 and 3 actively used the system in their daily lives with occupational therapy for the first 2 years. However, they later missed annual follow-up visits because they moved away or did not have continuing support from family members and because of the COVID-19 pandemic. When contacted by phone, they reported not using the system actively.

Discussion

Studies have indicated that patients who underwent Argus II retinal prosthesis implantation were found to have significantly more successful orientation, mobility, letter reading, reaching for and grasping objects, real-life activities, and reproducible phosphene perception when the device was active than when it was not active, and this success continued.^{8,9} The highest spatial resolution obtained with the Argus II retinal prosthesis was reported as 1.8 logMAR (Snellen 20/1262),⁶ and improvements in visual field examinations were also observed after implantation.¹⁰ The patients in our series achieved some abilities while actively using the Argus II epiretinal prosthesis system. Patient 2 was able to perceive obstacles and moving people in a room or corridor and move through without hitting them, find the door and door handle in a room, notice pictures and signs hanging on the wall, notice a plate on a table and find the spoon/fork and food on the plate, notice a contrasting drink in a glass, understand whether a glass is empty or full, and walk faster and more securely using the cane he used before. Patient 1 was able to accurately place high-contrast numbers of approximately 9 cm on a clock face, and patient 3 was able to trace a shape on a white background with her index finger marked black. The patients were able to apply some of these in their daily lives at home with the support of family members, but were mainly motivated when working with the occupational therapist.

In a large series of patients with Argus II implants, 24 adverse events were reported in 40% of patients in 5



Figure 7. Exercises conducted by patients while the Argus II epiretinal prosthesis implant is active, accompanied by an occupational therapist: Patient 1 accurately places numbers in the position on the clock face, patient 2 combines the letters to form words, and patient 3 indicates a small cube on a white plate by touching with her finger

years of follow-up, most of which occurred in the first year and consisted of conjunctival erosion, conjunctival dehiscence, hypotony, 3 cases of presumed endophthalmitis, and 1 case of rhegmatogenous retinal detachment.¹¹ With improvements in the surgical procedure, the incidence of hypotony decreased.¹² In a retrospective study of 274 patients who underwent Argus II between 2007 and 2017, conjunctival erosion was the most common adverse effect, observed in 60% of patients in the first 15 months and 85% in the first 2.5 years.¹³ No implant-related complications were observed in any of the patients in our series.

The electrical stimulus threshold can be defined as the current required for the patient to perceive a phosphene. The closer an electrode is to the retinal surface and the macula, and the more cell bodies are around it, the lower this threshold is.¹⁴ Lower thresholds are more desirable in terms of reducing electrode corrosion and enabling electrical stimulation of a large area. However, the situation seen in practice may be different. In one series of 3 cases, lower threshold values and better performance in 2 of the implanted patients were attributed to small implant-retina distance,¹⁵ whereas in another 5-case series evaluating electrical stimulation results based on implant-retina distance, it was reported that the functional relevance of this distance was patient-dependent, that complete apposition was not necessary to achieve good results, and that it could even reduce function by causing retinoschisis.¹⁶ In our study, initial threshold values were relatively higher in patient 1, who was older and had a more atrophic fovea. At 1-year follow-up, implant-retina distance was decreased as a result of reduced retinal cyst formation, and there was a decrease in the threshold values. In patient 3, however, retina-implant contact was only present at the implant margin, there was no direct contact with the electrodes, and threshold values were found to be lower.

Studies in the literature have examined and attempted to explain the development of retinal thickening, retinoschisis, and fibrosis at the implant-retinal interface, which we observed to a mild degree in patient 1 and more dramatically in patient 2 in our study. In a study examining the status of 18 consecutively implanted patients at 6-month follow-up, it was observed that compared to postoperative 1 month, 68.75% of the implants had rotated inferiorly and epiretinal membranes had formed at the implant-retinal interface.¹⁷ In another study of 20 eyes implanted with the Argus II retinal prosthesis and followed up with OCT, hyperreflective tissue resembling fibrosis at the implant-retina interface was observed on OCT in 10 and progression to retinoschisis in 9 of the eyes.¹⁸ In that case series, in which the mean age was 57.4 years and mean follow-up time was 36.8 months, fibrosis onset occurred at 2-33 months and retinoschisis onset occurred at 6-36 months. Retinoschisis showed no changes after development, and implant-retina distance was not associated with the development of fibrosis.¹⁸ The authors speculated that tack irritation or residual vitreous remaining after epiretinal membrane and hyaloid removal may have caused fibrosis and hyperproliferation, while retinoschisis developed secondary to fibrosis-related traction. There was no difference in the patients' visual functioning while the device was active.¹⁸ However, patient 1 in our series complained of a decline in function, so the fitting procedure was repeated and a revision of the threshold values was needed.

In a 52-year-old patient with RP who did not undergo epiretinal membrane peeling during implantation, retinal thickening and a hyperreflective band at the implant-retinal interface were detected at postoperative 1 year.¹⁹ The highest increase in threshold values corresponding to the area with

the thickest fibrosis suggests that the thick fibrosis may have prevented transmission. The authors speculated that electrical stimulation of the retina may have induced local biochemical changes and caused the rapid growth of existing epiretinal fibrosis, and that the slight continuous rotation of the implant may have caused chronic inflammation and fibrotic tissue proliferation by mechanical friction. In fact, based on a histopathological examination of fibrotic tissue surgically removed from the same patient at 2 years post-implantation, it was reported that the pathogenesis was an inflammatory process that led to sclerosis due to increased connective tissue accumulation resulting from a foreign body reaction, and the function of the implant increased after surgery.²⁰ In our series, we believe that long-term electrical stimulation and direct electro-retinal contact led to schisis-like retinal changes in patients 1 and 3, while fibrosis developing around the same time in patient 2 secondary to an excessive inflammatory response. However, postmortem histopathological examination of an eye implanted with the Argus II for 6 years revealed no additional damage in the nerve fiber region corresponding to the implant area and the total neuron count in the macular region did not differ from that in the fellow eye, while the neuron count around the retinal tack was lower compared to other perimacular areas, and fibrotic membrane formation was observed only in and around the tack insertion site.²¹ In a preclinical study of long-term electrical stimulation, hyperfluorescence due to staining in the tack area was observed on follow-up fluorescein angiography and fibrous tissue in the tack area and fibrous proliferation in the surrounding retina were observed on histopathological examination.²² In the first patient in our series, no significant capillary non-perfusion or neovascularization was detected under the implant on OCTA at 1-year follow-up.⁵

In a recent study, the IMIE 256 epiretinal prosthesis containing 256 electrodes was implanted in 5 Chinese patients, 4 with RP and 1 with Usher syndrome, and was explanted after 90 days as per protocol.²³ This implant is based on a working principle similar to that of the Argus II epiretinal prosthesis, with an electrode array 4.75x6.50 mm in size, and 4 of the patients achieved a visual acuity of 20/1200. Studies to improve the safety, feasibility, resolution, and functionality of epiretinal prostheses, especially in patients with end-stage hereditary retinal degeneration, are ongoing. The functional results, clinical findings, anatomical data, and imaging features obtained in the follow-up of patients who have an epiretinal implant and electrically active use of the device are important for establishing cause-effect relationships and directing future projects.

Acknowledgements: We would like to thank Mehmet Recai Arslantaş (İstanbul Aydın University, Biomedical Engineer) and Seval Cevher (University of Health Sciences Türkiye, Şişli Hamidiye Etfal Training and Research Hospital, Eye Clinic, Occupational Therapy) for their contributions to this project.

Ethics

Informed Consent: Obtained.

Peer-review: Externally peer reviewed.

Authorship Contributions

Surgical and Medical Practices: D.G., Concept: D.G., Design: D.G., E.D., Data Collection or Processing: D.G., O.K.O., C.G., Analysis or Interpretation: D.G., E.D., Literature Search: D.G., E.D., O.K.O., C.G., Writing: D.G.

Conflict of Interest: No conflict of interest was declared by the authors.

Financial Disclosure: The authors declared that this study received no financial support.

References

- Bloch E, Luo Y, da Cruz L. Advances in retinal prosthesis systems. *Ther Adv Ophthalmol*. 2019;11:2515841418817501.
- Luo YH, da Cruz L. The Argus® II Retinal Prosthesis System. *Prog Retin Eye Res*. 2016;50:89-107.
- Humayun MS, Dorn JD, Ahuja AK, Caspi A, Filley E, Dagnelie G, Salzmann J, Santos A, Duncan J, daCruz L, Mohand-Said S, Elliott D, McMahon MJ, Greenberg RJ. Preliminary 6 month results from the Argus II epiretinal prosthesis feasibility study. *Annu Int Conf IEEE Eng Med Biol Soc*. 2009;2009:4566-4568.
- Güven D, Demir M, Üke Uzun S, Ergen E, Tiryaki Demir S, Demir AG, Kaçar H. Evaluation of Demographical and Clinical Characteristics of Retinitis Pigmentosa Patients Screened for Argus II Retinal Prosthesis Candidacy. *Journal of Retina Vitreous*. 2016;24:61-69.
- Güven D, Demir M, Özcan D, Kaçar H, Demir ST, Uzun SÜ. Multimodal Imaging Including Optical Coherence Tomography Angiography of a Patient With Argus II Retinal Prosthesis One Year After Implantation. *Ophthalmic Surg Lasers Imaging Retina*. 2018;49:55-59.
- Humayun MS, Dorn JD, da Cruz L, Dagnelie G, Sahel JA, Stanga PE, Cideciyan AV, Duncan JL, Elliott D, Filley E, Ho AC, Santos A, Safran AB, Arditi A, Del Priore LV, Greenberg RJ; Argus II Study Group. Interim results from the international trial of Second Sight's visual prosthesis. *Ophthalmology*. 2012;119:779-788.
- Güven D. 17. Bölüm: Retina Replasmanı ve Retinada Restoratif Tedavi Yaklaşımları, Retinal İmplant Uygulamaları. *Güncel Vitreoretinal Cerrahi*, Editörler: Yılmaz G, Durukan AH, 1. Baskı. Ankara, Anadolu Kitabevi; 2021;755-759.
- Dagnelie G, Christopher P, Arditi A, da Cruz L, Duncan JL, Ho AC, Olmos de Koo LC, Sahel JA, Stanga PE, Thumann G, Wang Y, Arsiero M, Dorn JD, Greenberg RJ; Argus® II Study Group. Performance of real-world functional vision tasks by blind subjects improves after implantation with the Argus® II retinal prosthesis system. *Clin Exp Ophthalmol*. 2017;45:152-159.
- Luo YH, Zhong JJ, Cleo M, da Cruz L. Long-term Repeatability and Reproducibility of Phosphene Characteristics in Chronically Implanted Argus II Retinal Prosthesis Subjects. *Am J Ophthalmol*. 2016;170:100-109.
- Rizzo S, Belting C, Cinelli L, Allegrini L. Visual field changes following implantation of the Argus II retinal prosthesis. *Graefes Arch Clin Exp Ophthalmol*. 2015;253:323-325.
- da Cruz L, Dorn JD, Humayun MS, Dagnelie G, Handa J, Barale PO, Sahel JA, Stanga PE, Hafezi F, Safran AB, Salzmann J, Santos A, Birch D, Spencer R, Cideciyan AV, de Juan E, Duncan JL, Elliott D, Fawzi A, Olmos de Koo LC, Ho AC, Brown G, Haller J, Regillo C, Del Priore LV, Arditi A, Greenberg RJ; Argus II Study Group. Five-Year Safety and Performance Results from the Argus II Retinal Prosthesis System Clinical Trial. *Ophthalmology*. 2016;123:2248-2254.
- Rizzo S, Barale PO, Ayello-Scheer S, Devenyi RG, Delyfer MN, Korobelnik JF, Rachitskaya A, Yuan A, Jayasundera KT, Zacks DN, Handa JT, Montezuma SR, Koozekanani D, Stanga P, da Cruz L, Walter P, Augustin AJ, Olmos de Koo LC, Ho AC, Kirchoff B, Hahn P, Vajzovic L, Iezzi R, Gaucher D, Arevalo JF, Gregori NZ, Wiedemann P, Özmert E, Lim JJ, Rezende FA, Huang SS, Merlini F, Patel U, Greenberg RJ, Justus S, Bacherini D, Cinelli L, Humayun

- MS. Hypotony and the Argus II retinal prosthesis: causes, prevention and management. *Br J Ophthalmol*. 2020;104:518-523.
13. Rizzo S, Barale PO, Ayello-Scheer S, Devenyi RG, Delyfer MN, Korobelnik JF, Rachitskaya A, Yuan A, Jayasundera KT, Zacks DN, Handa JT, Montezuma SR, Koozekanani D, Stanga PE, da Cruz L, Walter P, Augustin AJ, Chizzolini M, Olmos de Koo LC, Ho AC, Kirchoff B, Hahn P, Vajzovic L, Iezzi R Jr, Gaucher D, Arevalo JF, Gregori NZ, Grisanti S, Özmert E, Yoon YH, Kokame GT, Lim JJ, Szurman P, de Juan E Jr, Rezende FA, Salzmann J, Richard G, Huang SS, Merlini F, Patel U, Cruz C, Greenberg RJ, Justus S, Cinelli L, Humayun MS. ADVERSE EVENTS OF THE ARGUS II RETINAL PROSTHESIS: Incidence, Causes, and Best Practices for Managing and Preventing Conjunctival Erosion. *Retina*. 2020;40:303-311.
 14. Ahuja AK, Behrend MR. The Argus™ II retinal prosthesis: factors affecting patient selection for implantation. *Prog Retin Eye Res*. 2013;36:1-23.
 15. Parmeggiani F, De Nadai K, Piovan A, Binotto A, Zamengo S, Chizzolini M. Optical coherence tomography imaging in the management of the Argus II retinal prosthesis system. *Eur J Ophthalmol*. 2017;27:e16-e21.
 16. Naidu A, Ghani N, Yazdanie MS, Chaudhary K. Effect of the electrode array-retina gap distance on visual function in patients with the Argus II retinal prosthesis. *BMC Ophthalmol*. 2020;20:366.
 17. Delyfer MN, Gaucher D, Govare M, Cougnard-Grégoire A, Korobelnik JF, Ajana S, Mohand-Said S, Ayello-Scheer S, Rezaiguia-Studer F, Dollfus H, Sahel JA, Barale PO. Adapted Surgical Procedure for Argus II Retinal Implantation: Feasibility, Safety, Efficiency, and Postoperative Anatomic Findings. *Ophthalmol Retina*. 2018;2:276-287.
 18. Rizzo S, Cinelli L, Finocchio L, Tartaro R, Santoro F, Gregori NZ. Assessment of Postoperative Morphologic Retinal Changes by Optical Coherence Tomography in Recipients of an Electronic Retinal Prosthesis Implant. *JAMA Ophthalmol*. 2019;137:272-278.
 19. Patelli F, Colombo L, Aly MOM, Rossetti L. Anatomical Changes Between Argus II Retinal Prosthesis And Inner Retinal Layers Detected By Spectral Domain Optical Coherence Tomography In First Year: A Case Report. *Retin Cases Brief Rep*. 2021;15:457-461.
 20. Patelli F, Falleni M, Colombo L, Martinelli C, Tosi D, Bulfamante G, Rossetti L. Epiretinal Fibrosis Removal In An Argus II-Implanted Eye: Histological Characteristics and Functional Results. *Retina*. 2020;40:2403-2409.
 21. Lin TC, Wang LC, Yue L, Zhang Y, Falabella P, Zhu D, Hinton DR, Rao NA, Birch DG, Spencer R, Dorn JD, Humayun MS. Histopathologic Assessment of Optic Nerves and Retina From a Patient With Chronically Implanted Argus II Retinal Prosthesis System. *Transl Vis Sci Technol*. 2019;8:31.
 22. Güiven D, Weiland JD, Fujii G, Mech BV, Mahadevappa M, Greenberg R, Roizenblatt R, Qiu G, Labree L, Wang X, Hinton D, Humayun MS. Long-term stimulation by active epiretinal implants in normal and RCD1 dogs. *J Neural Eng*. 2005;2:S65-S73.
 23. Xu H, Zhong X, Pang C, Zou J, Chen W, Wang X, Li S, Hu Y, Sagan DS, Weiss PT, Yao Y, Xiang J, Dayan MS, Humayun MS, Tai YC. First Human Results With the 256 Channel Intelligent Micro Implant Eye (IMIE 256). *Transl Vis Sci Technol*. 2021;10:14.